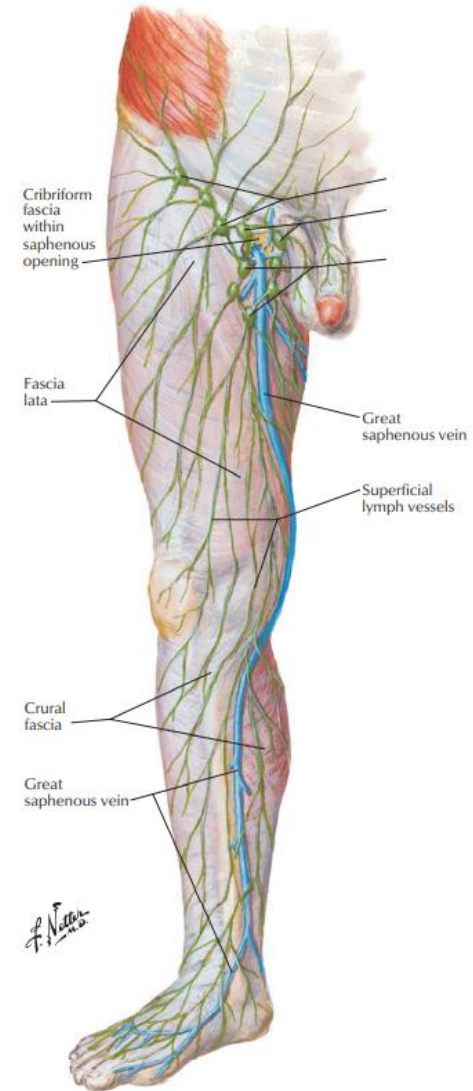
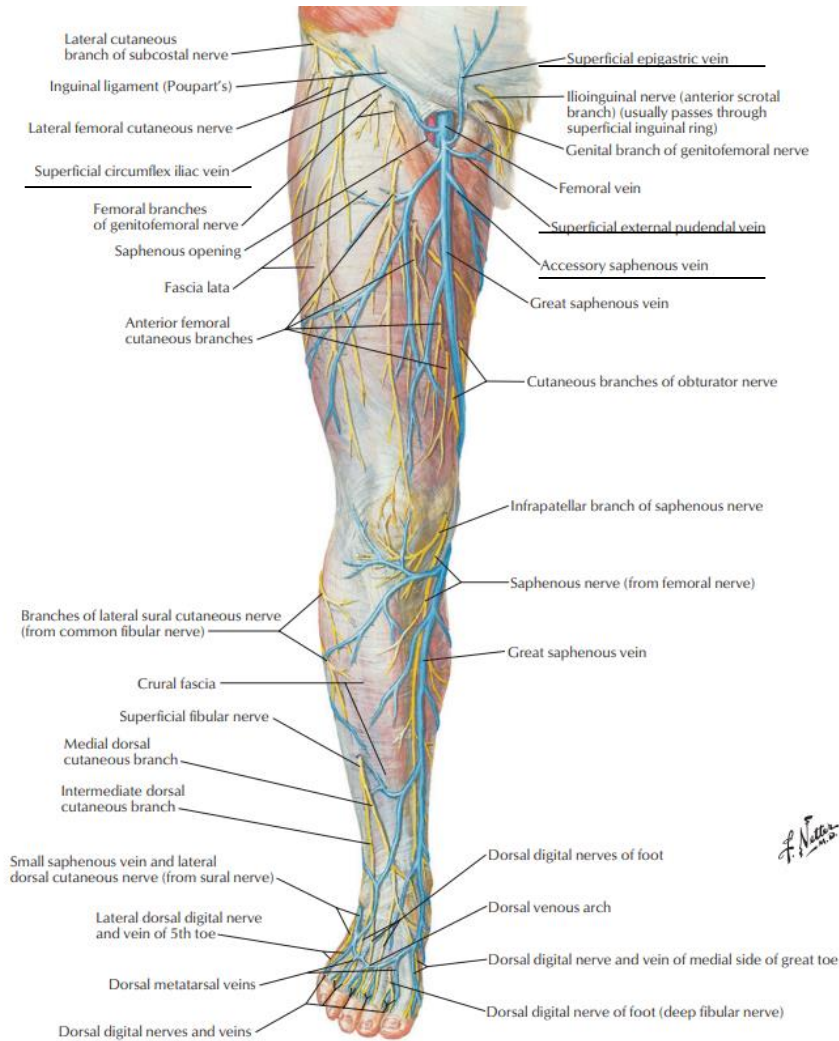


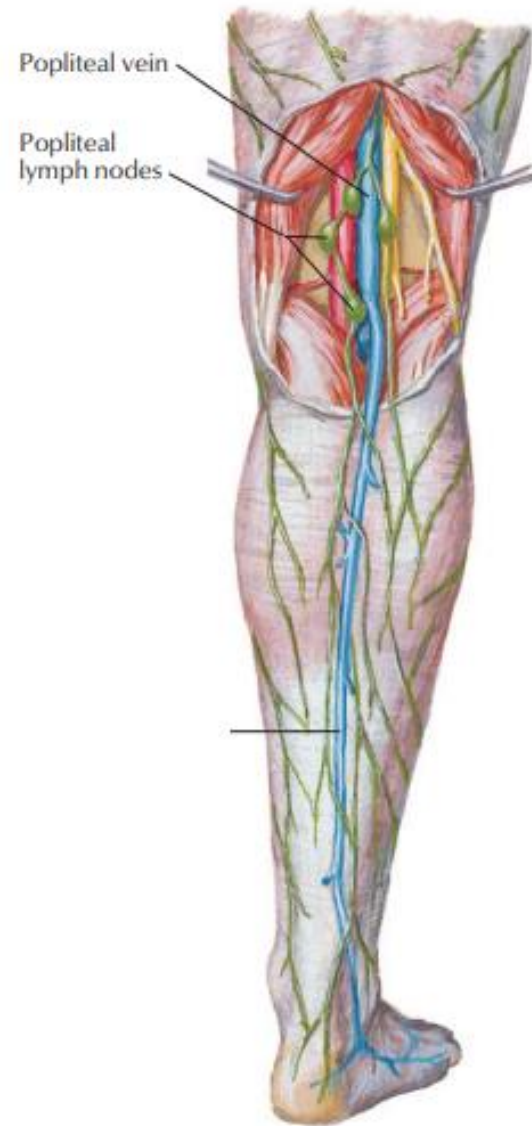
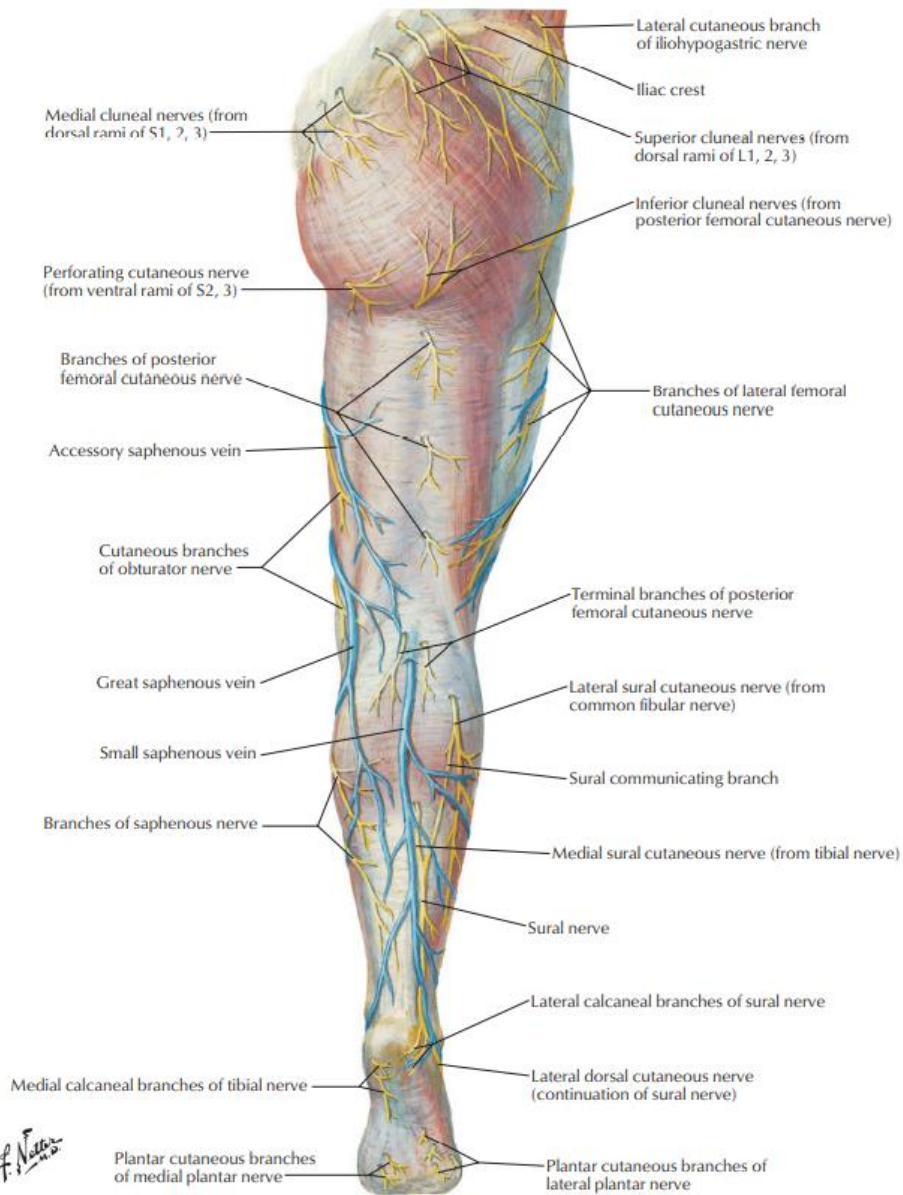
TROMBOEMBOLISMO PULMONAR

Chiara Beletato

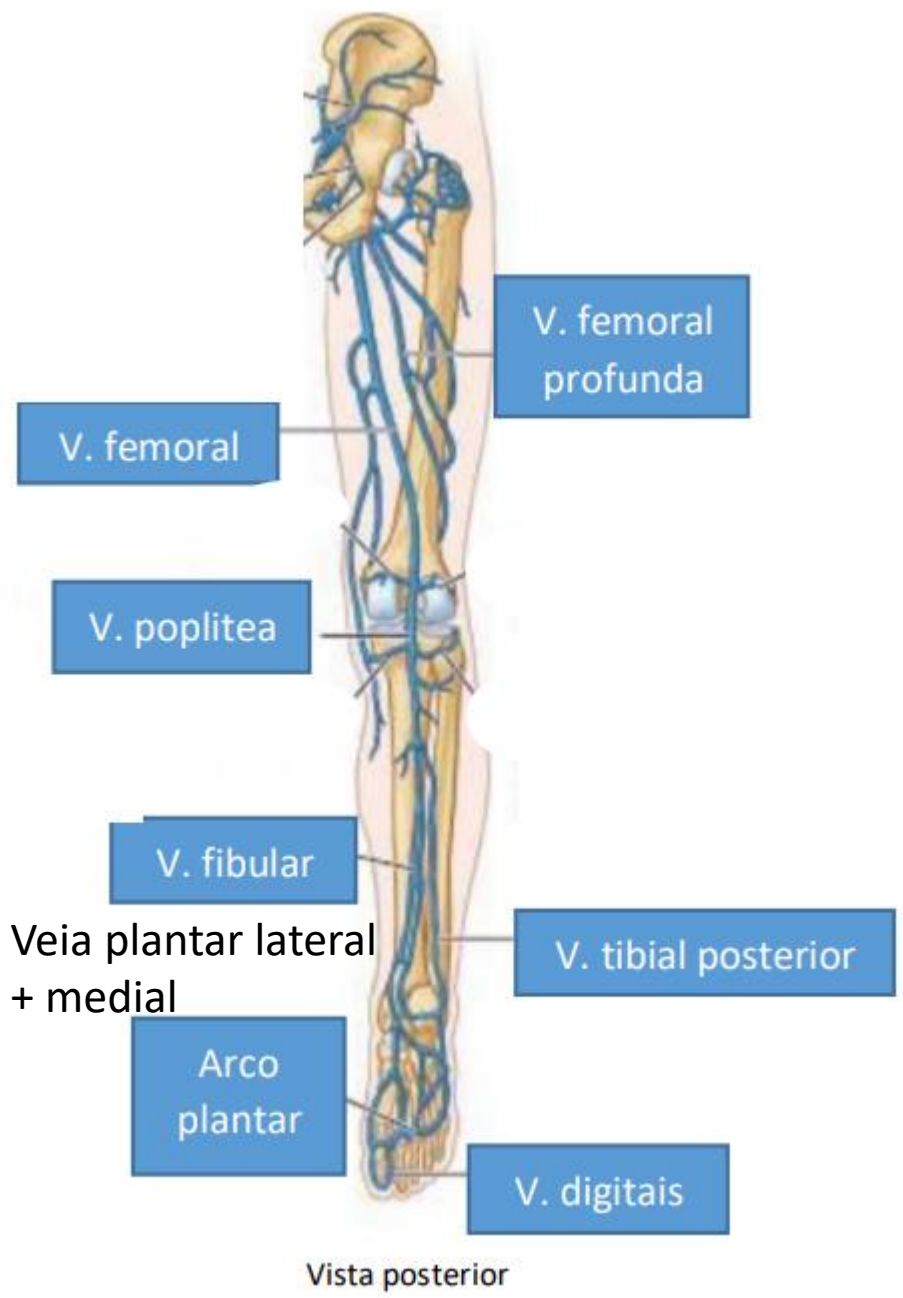
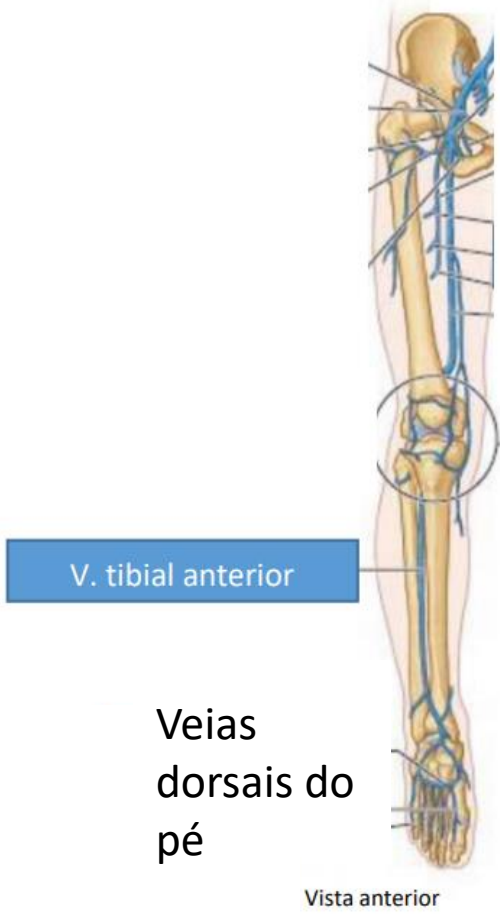
Sistema Venoso

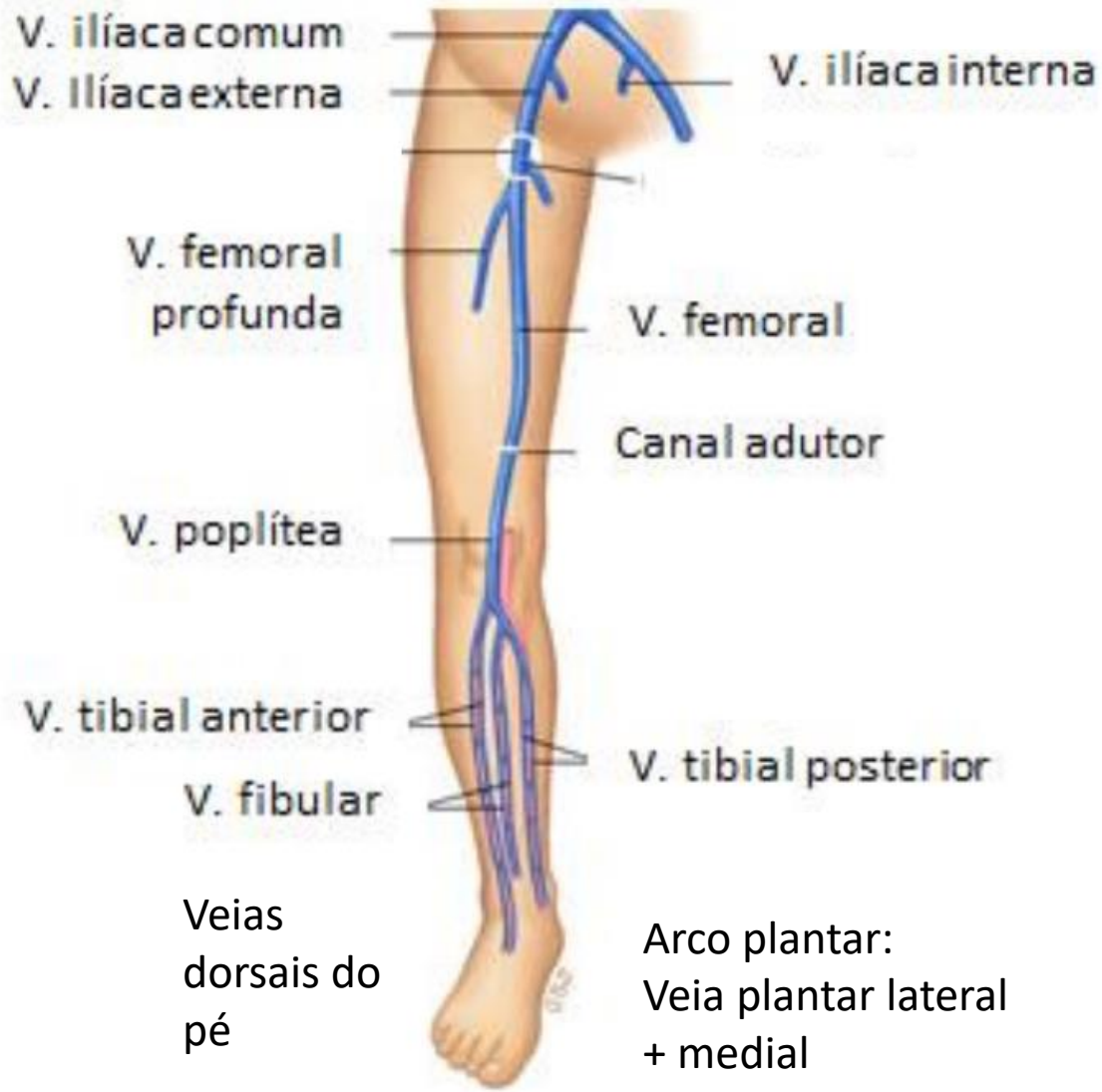
Veia Cava Inferior

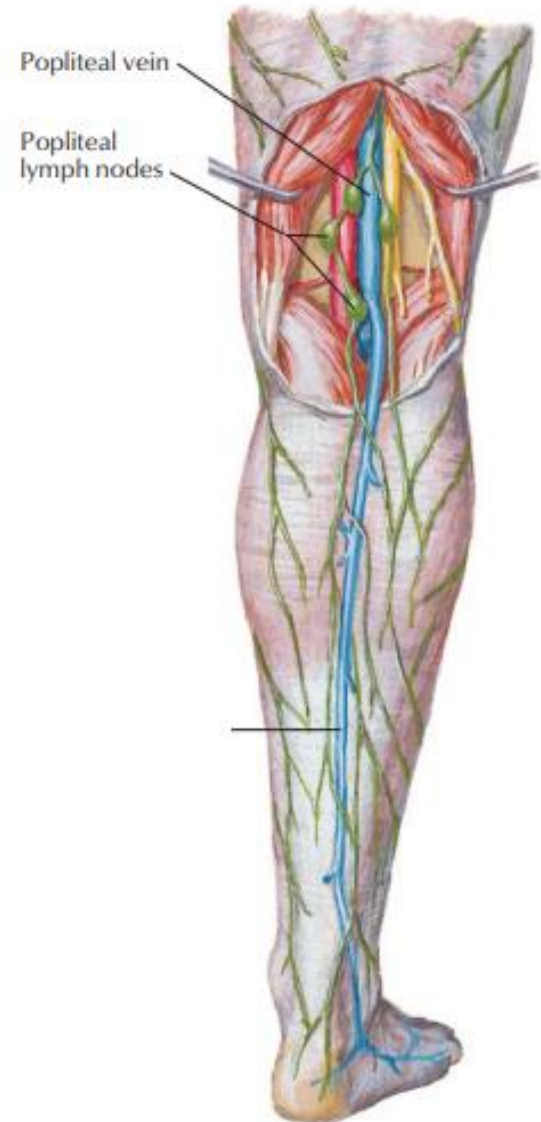
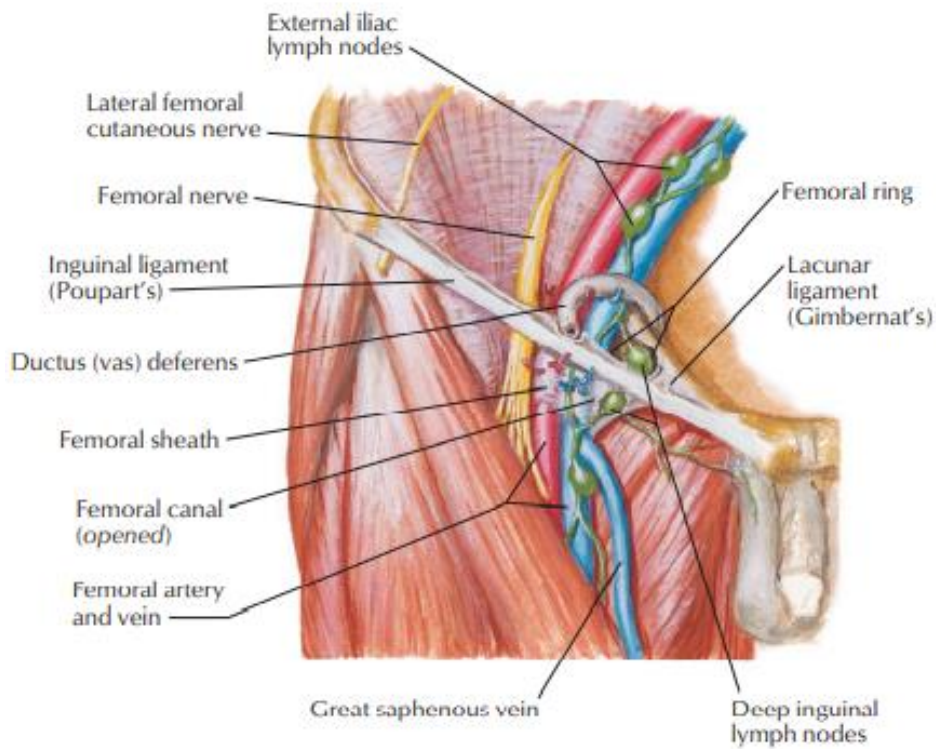


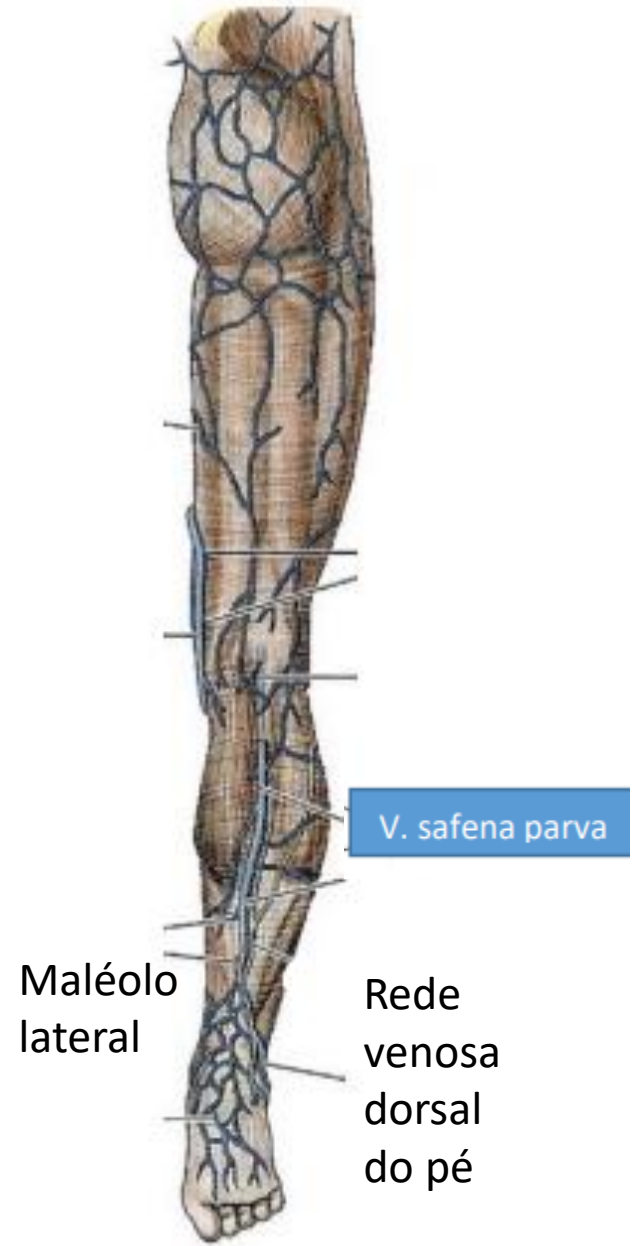
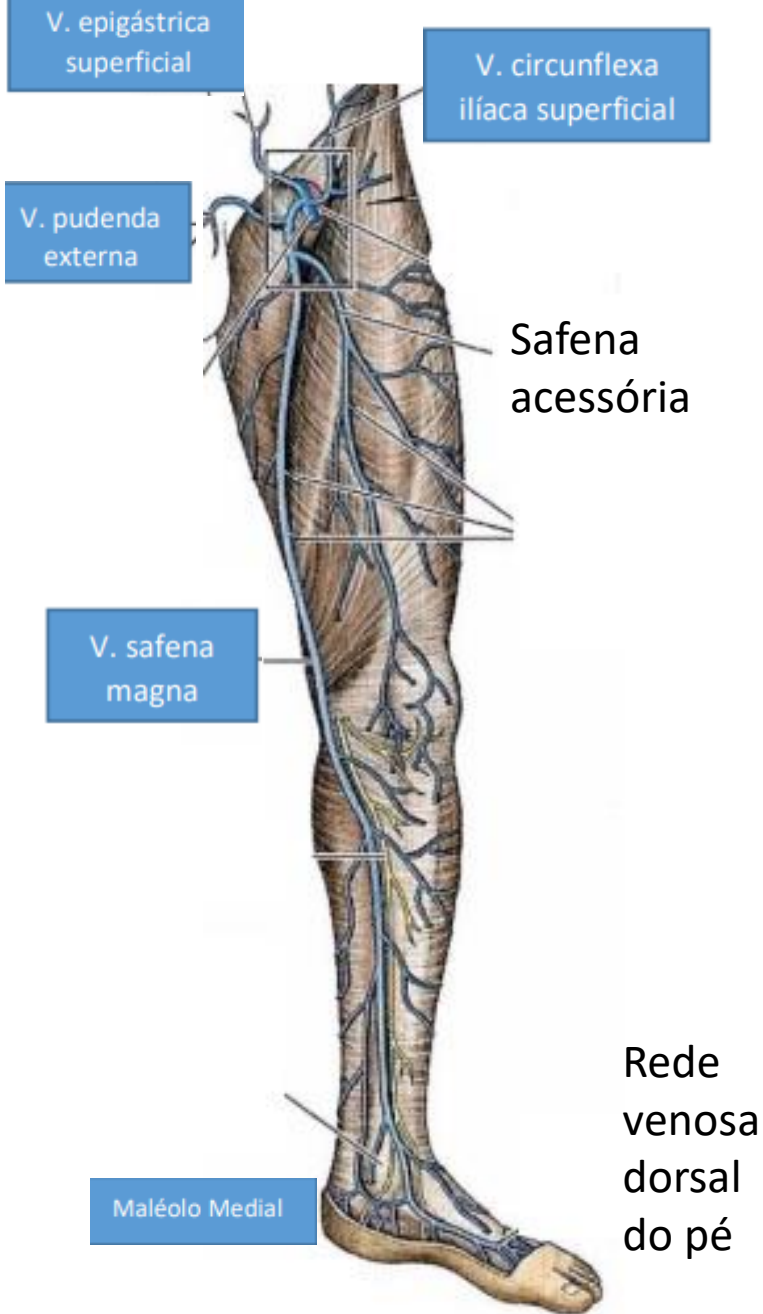


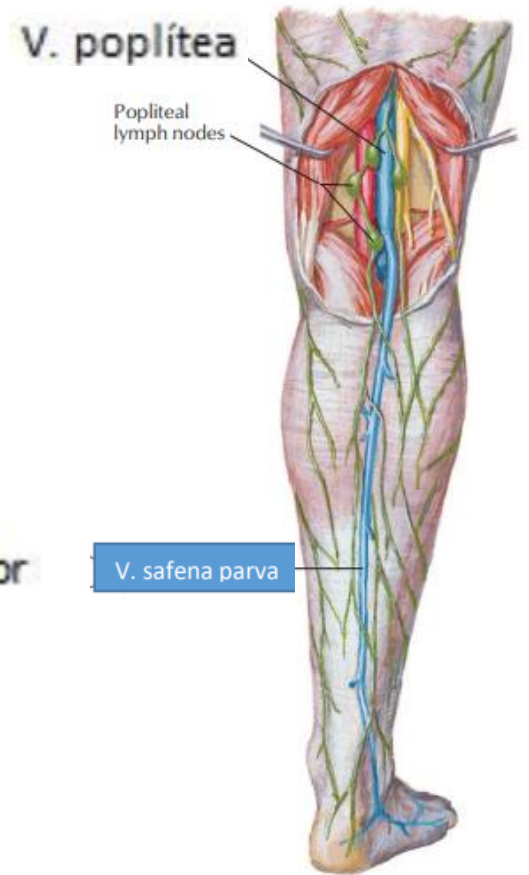
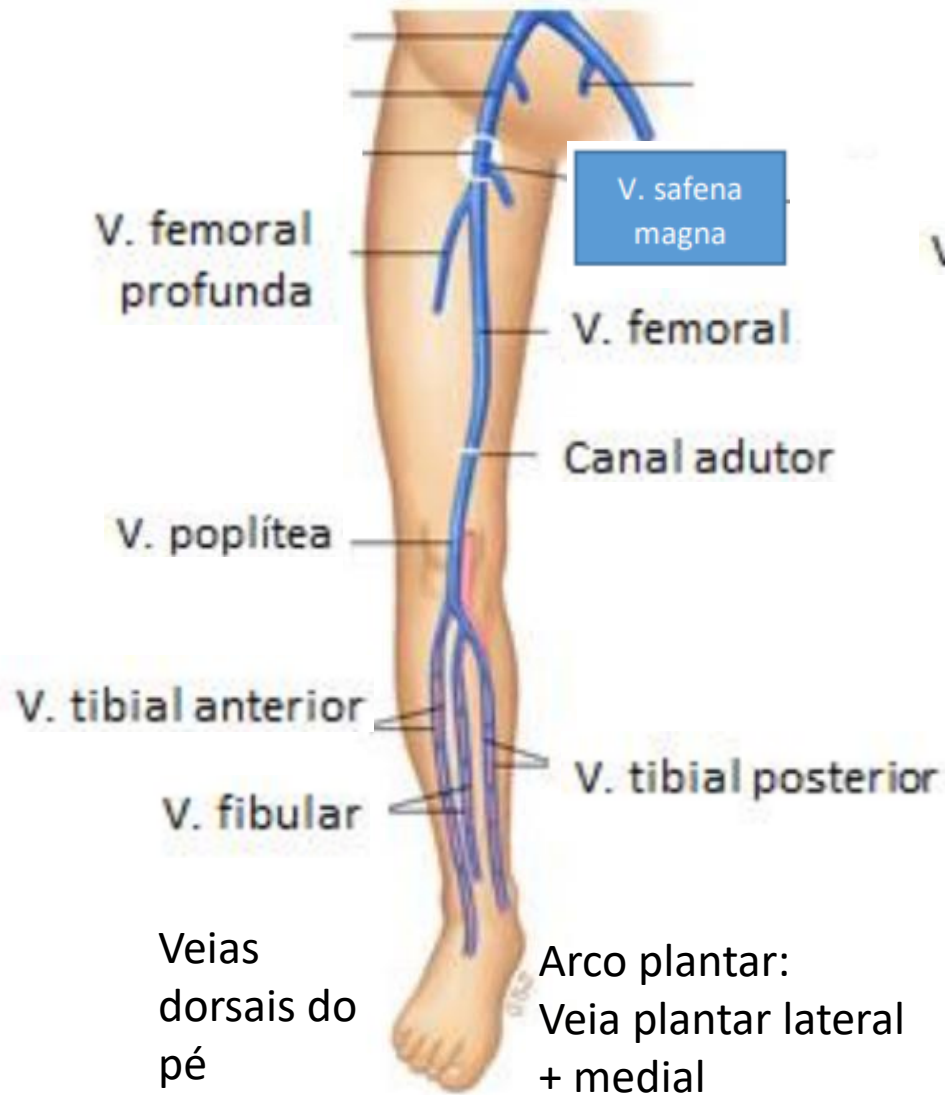
F. Netter M.D.

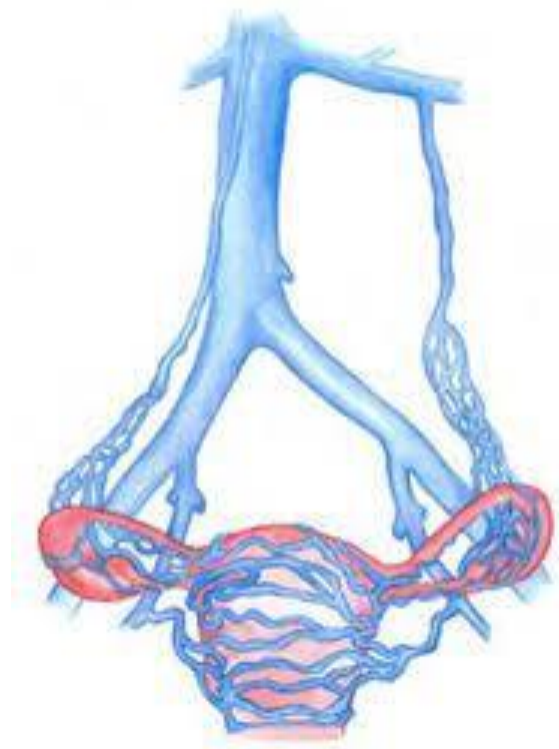
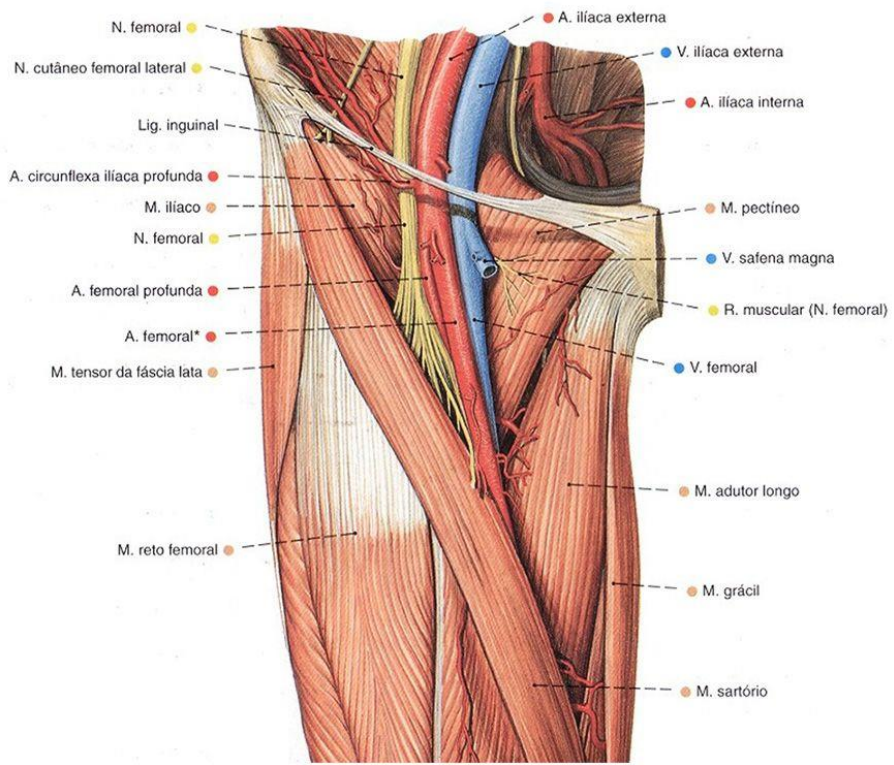






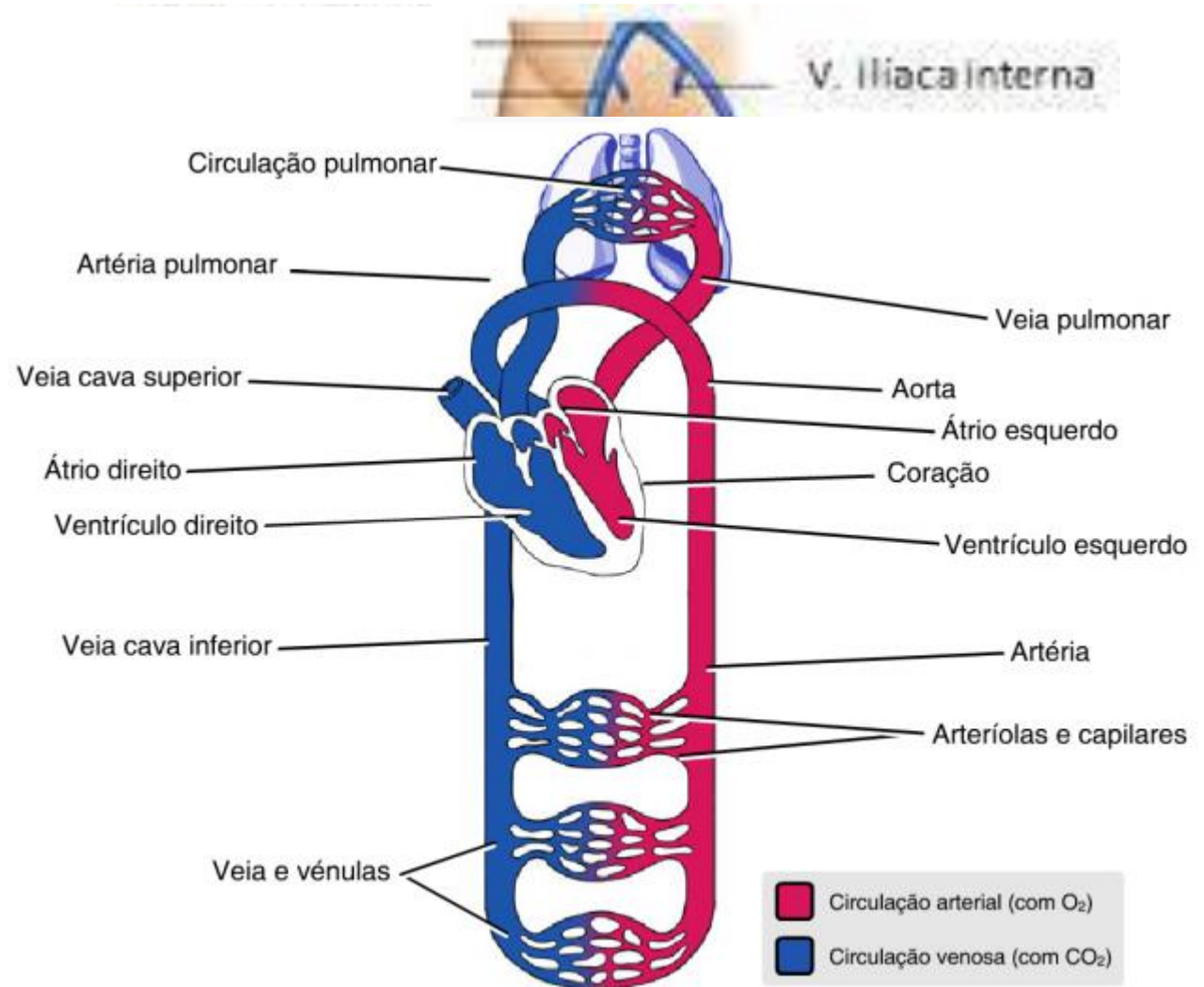




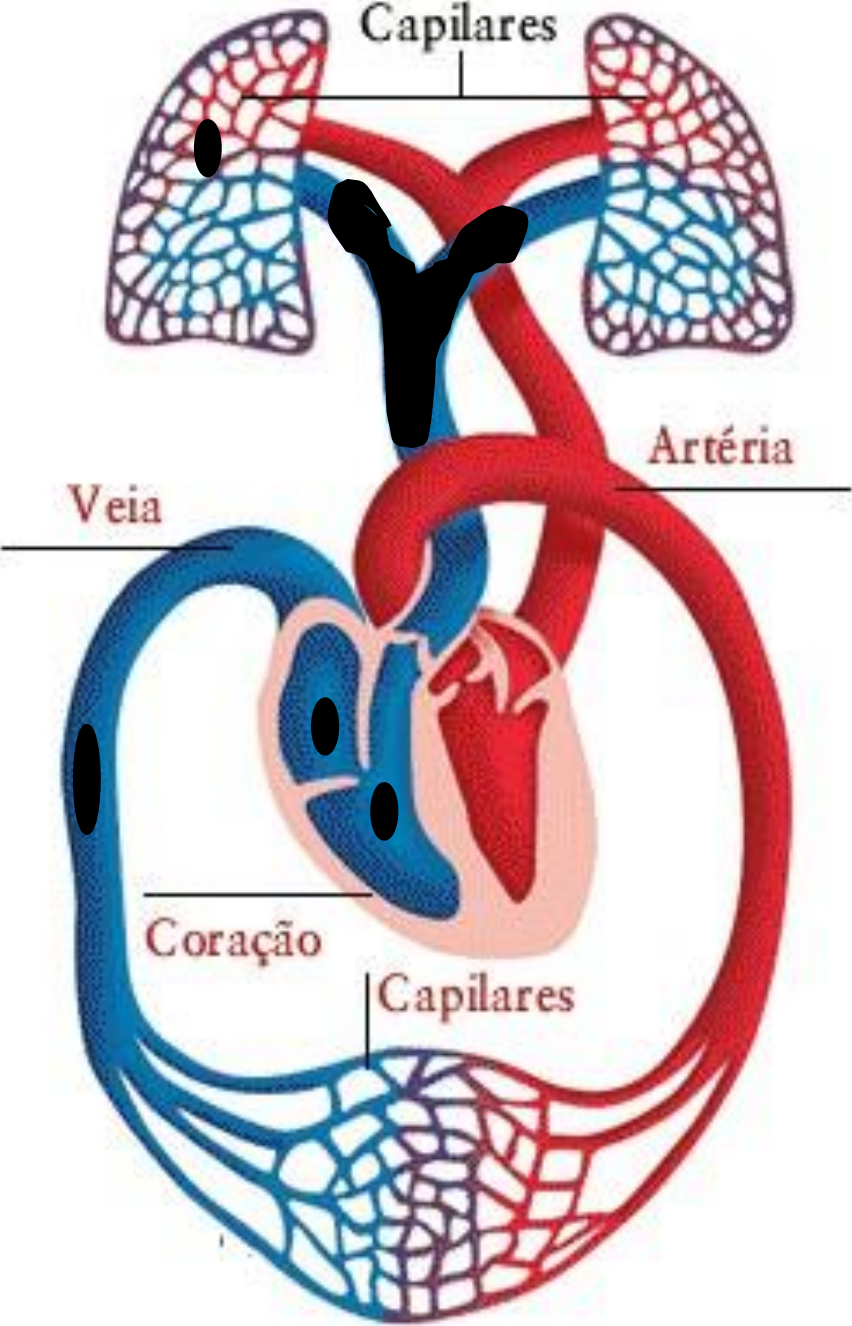


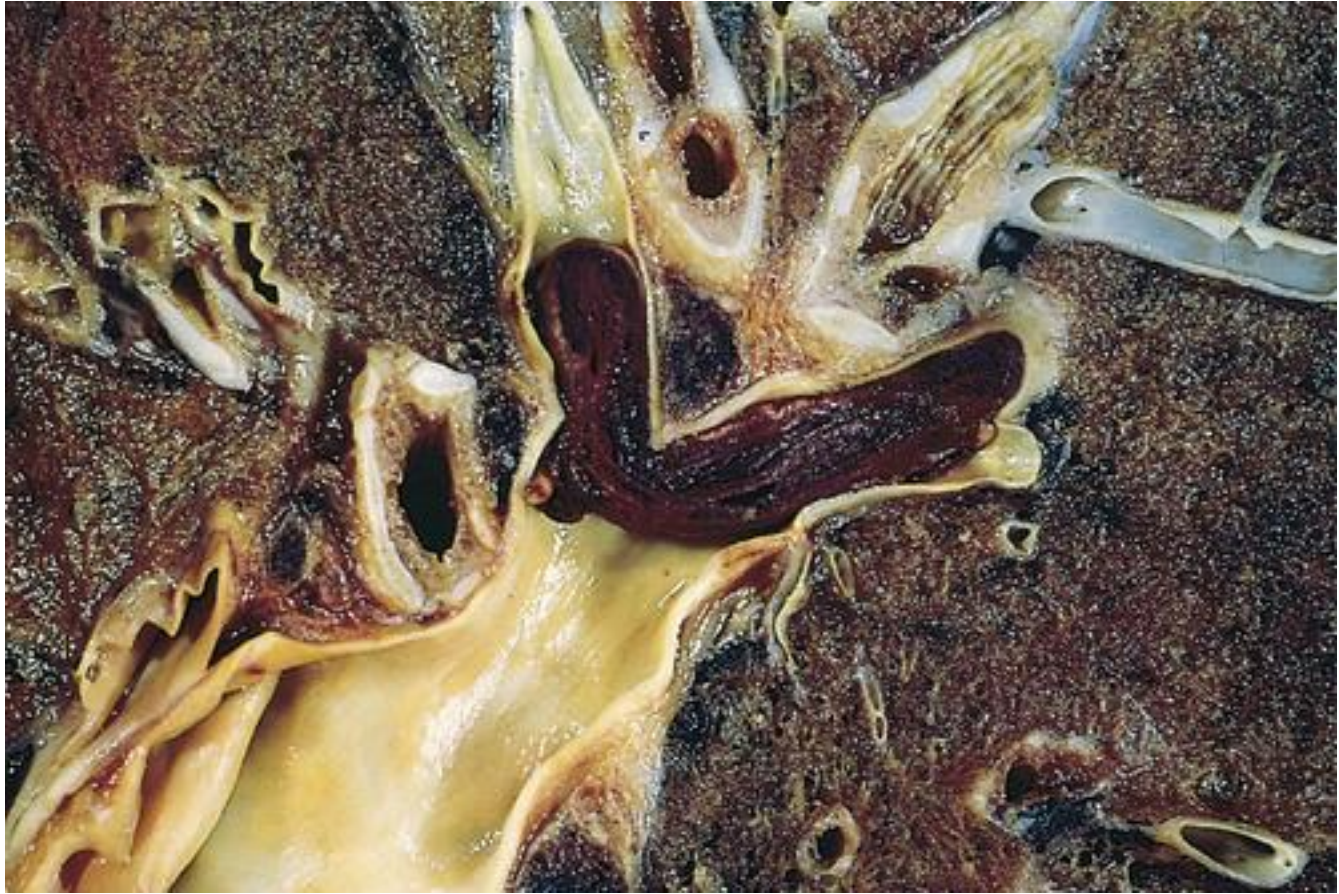TROMBOEMBOLISMO PULMONAR

- TVP → TEP



Ocorrência súbita





TEP

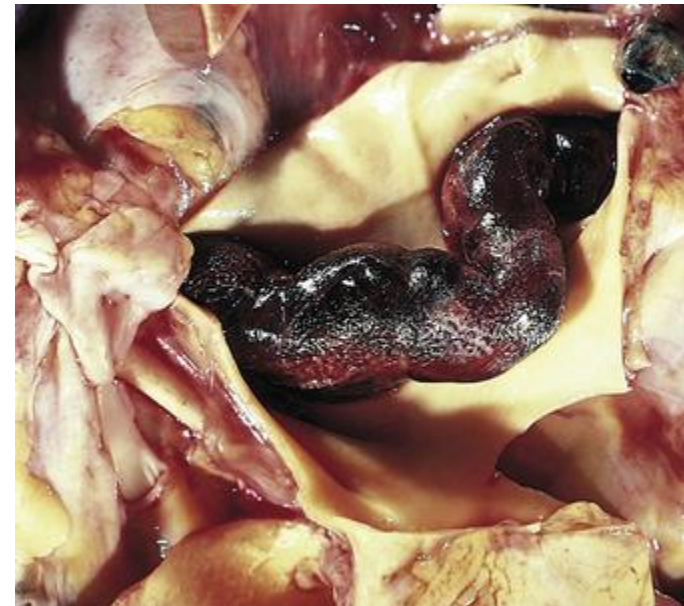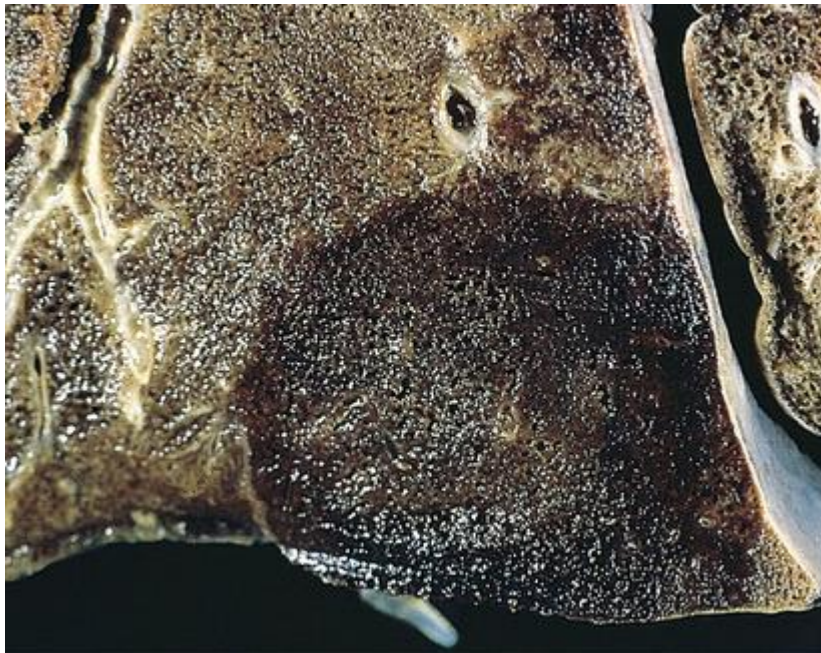
- Condição associadas com a hipercoagulabilidade;
- Origem embólica;

Tromboembolismo Pulmonar

- Fatores de risco:
 - Hipercoagulabilidade
 - Primária
 - Secundária
 - Imobilização
 - Patologias cardíacas
 - Câncer
 - Fraturas de quadril
 - ACO

Tromboembolismo pulmonar

- Morfologia
 - Grandes êmbolos nas artérias pulmonares
 - Êmbolos menores → vasos periféricos



TEP

- Curso clínico
 - Dor torácica (pleurítica)
 - Hemoptíase
 - Sibilância
 - Taquipneia
 - Dispneia

Bibliografia

- Robbins 9 ed