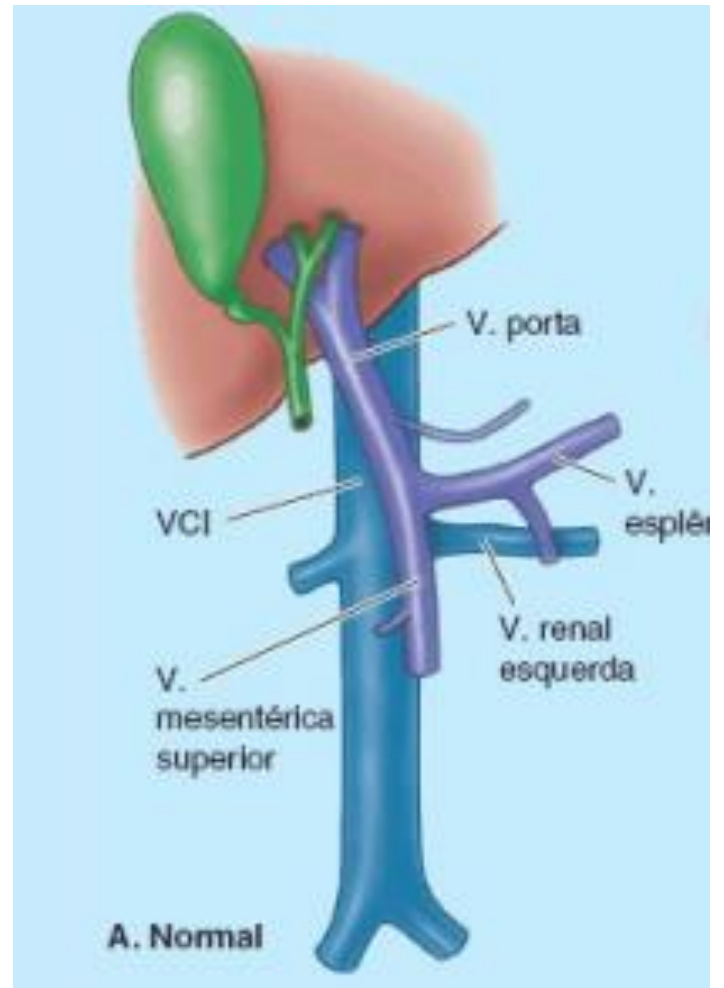
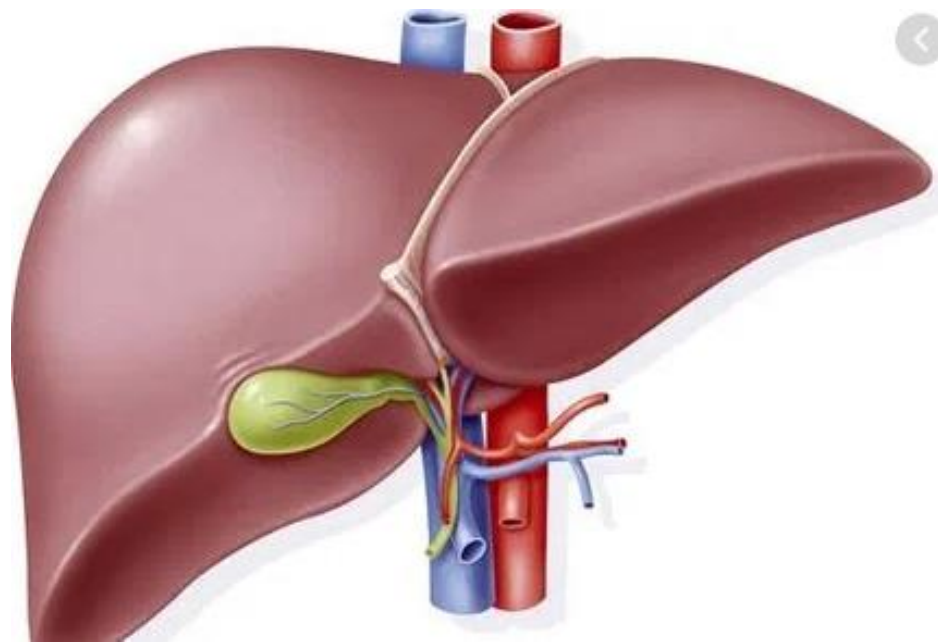
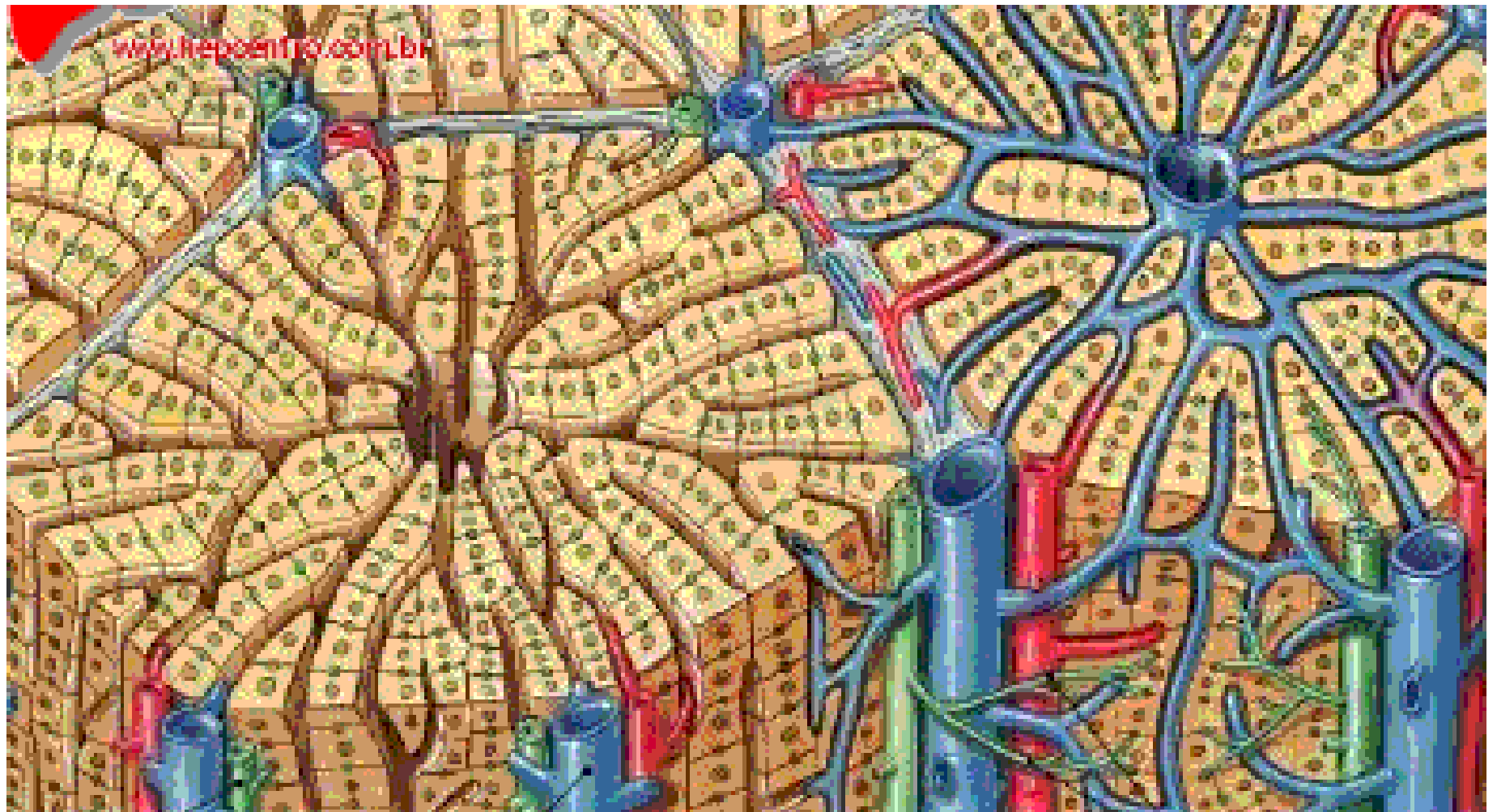
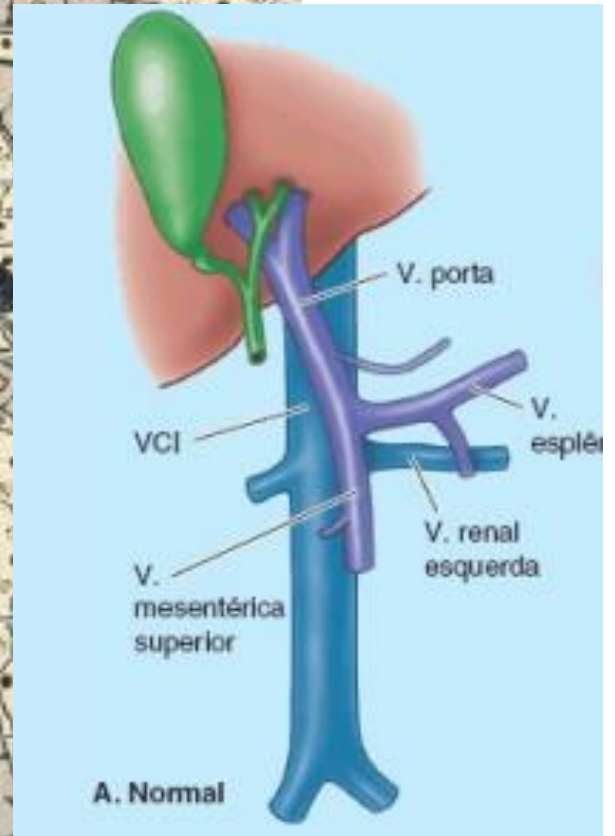
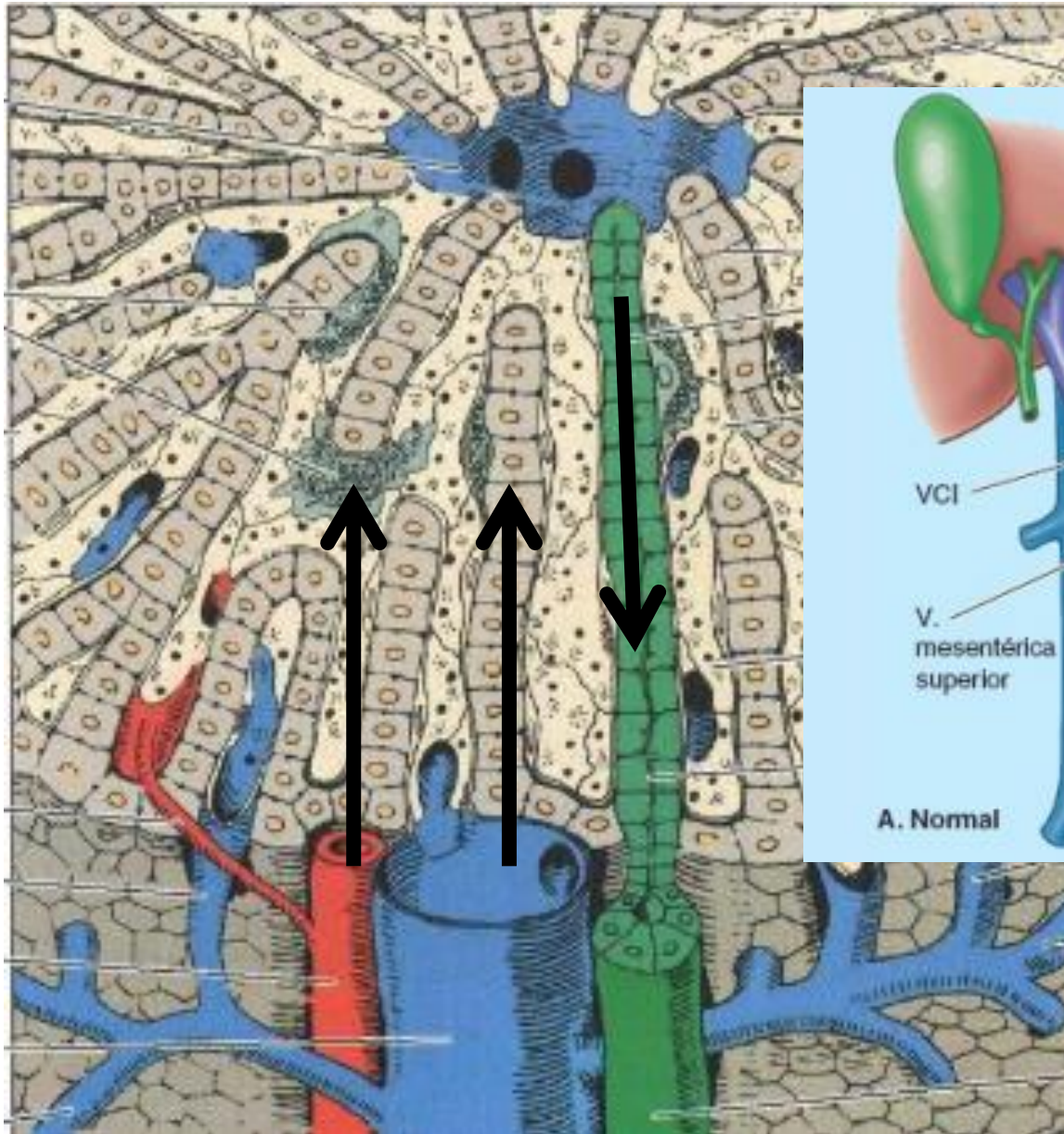


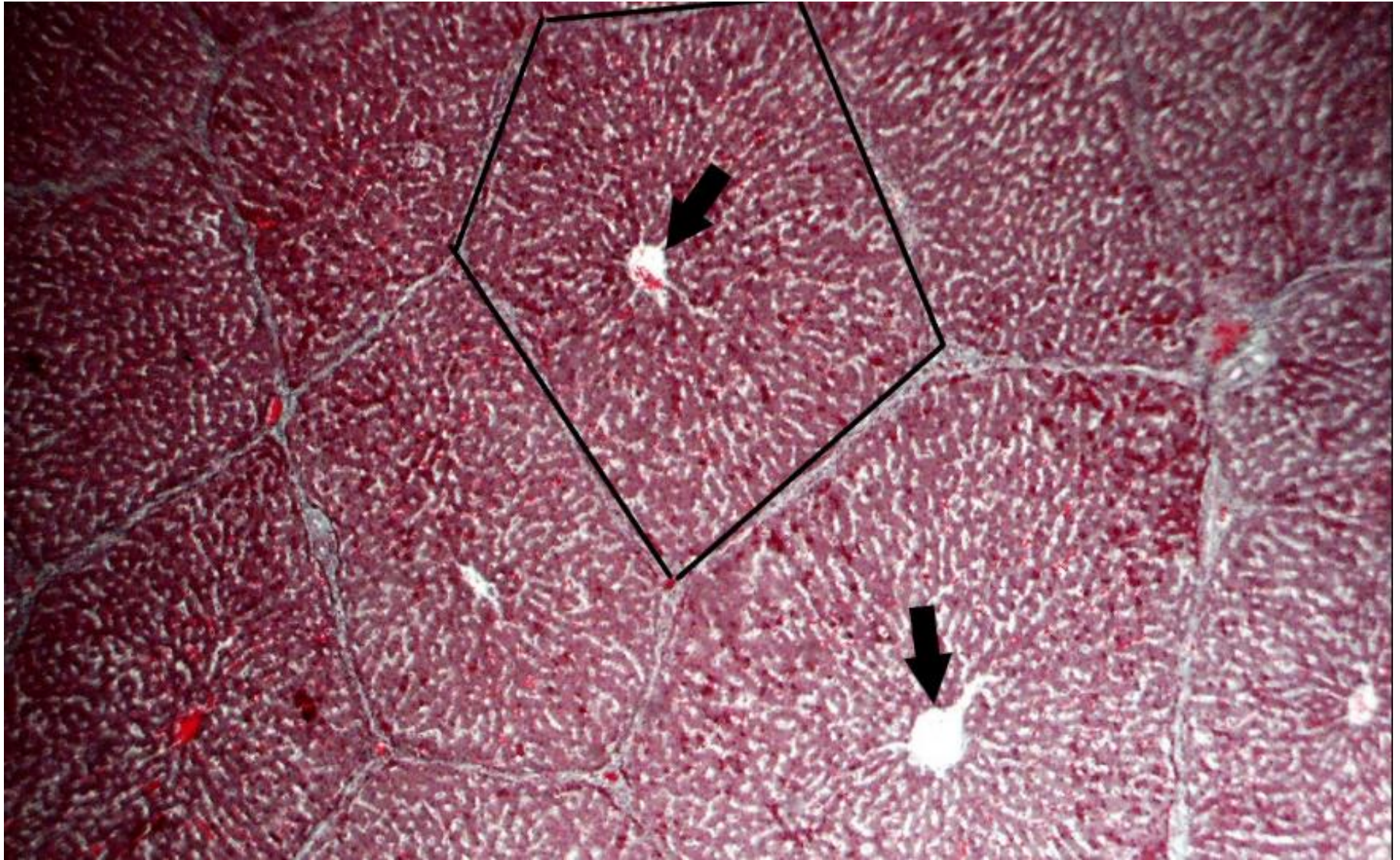
# Patologias do Fígado e Trato Biliar

Chiara Beletato





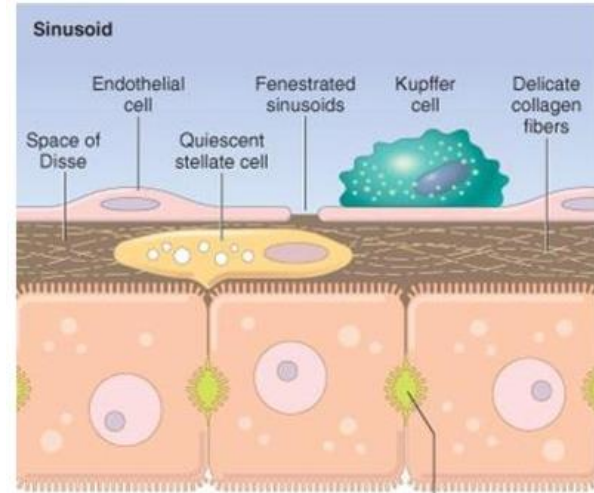
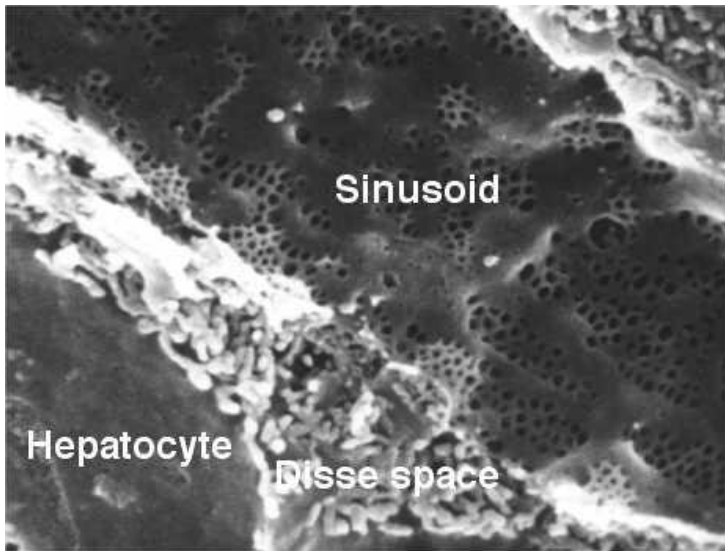
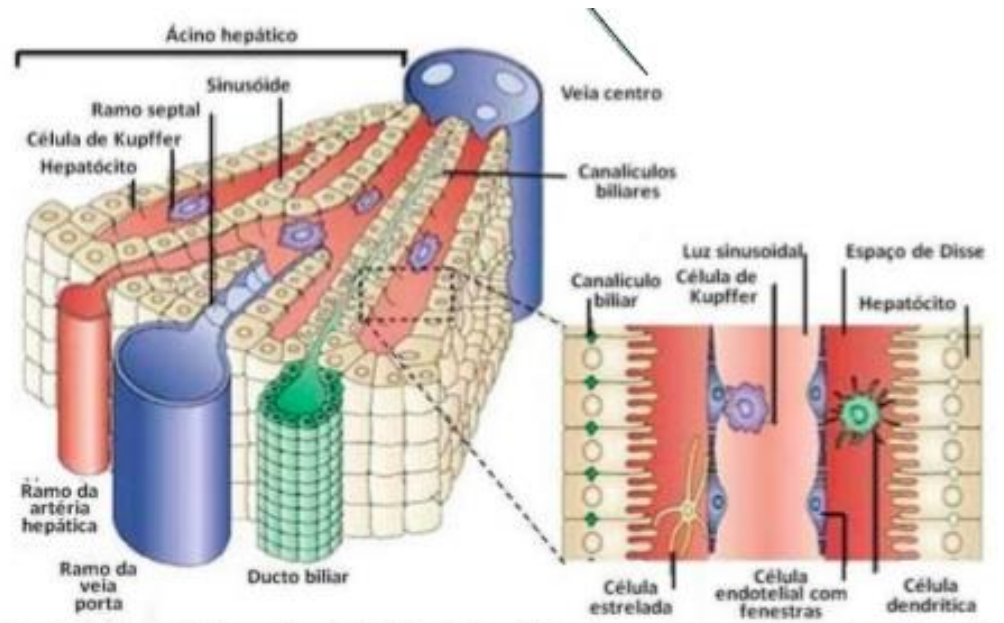
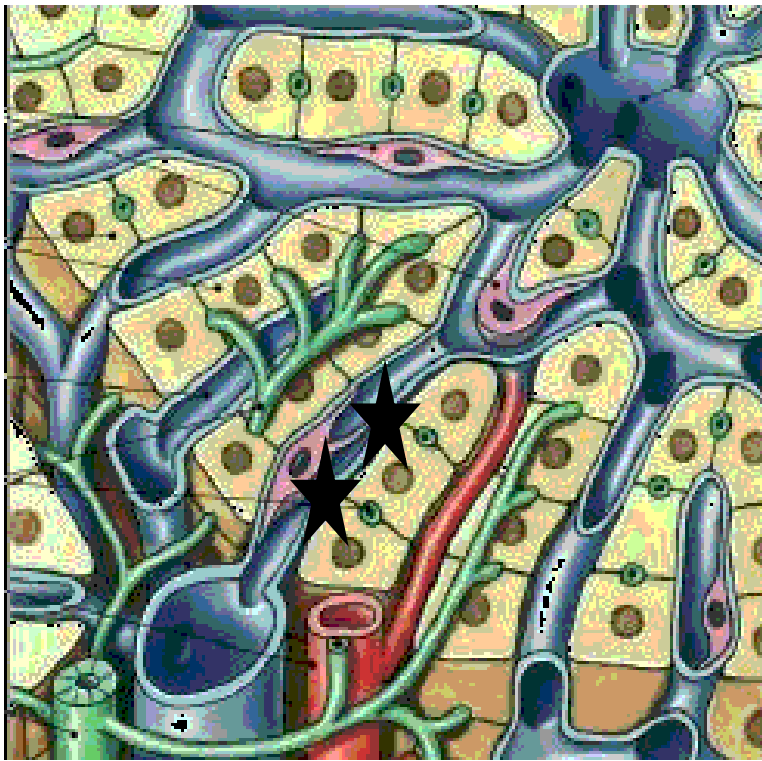




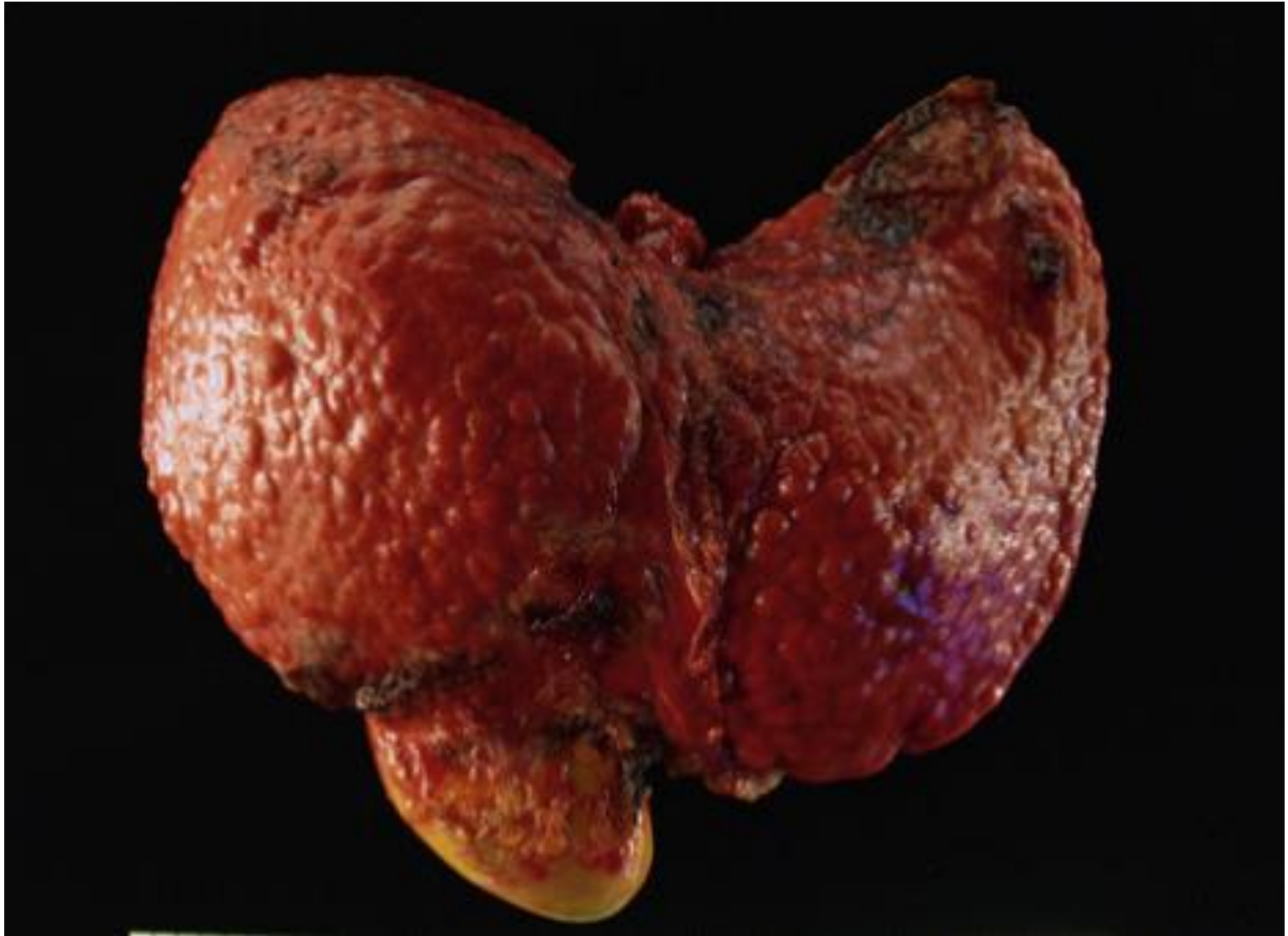# CIRROSE HEPÁTICA

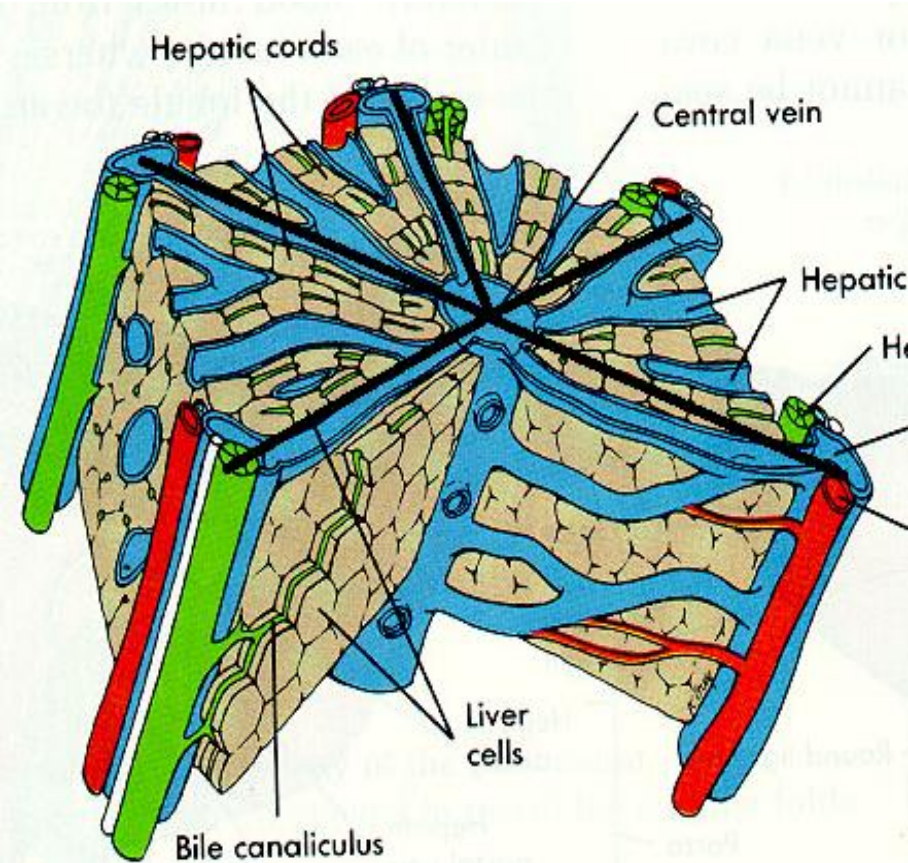
# Cirrose Hepática

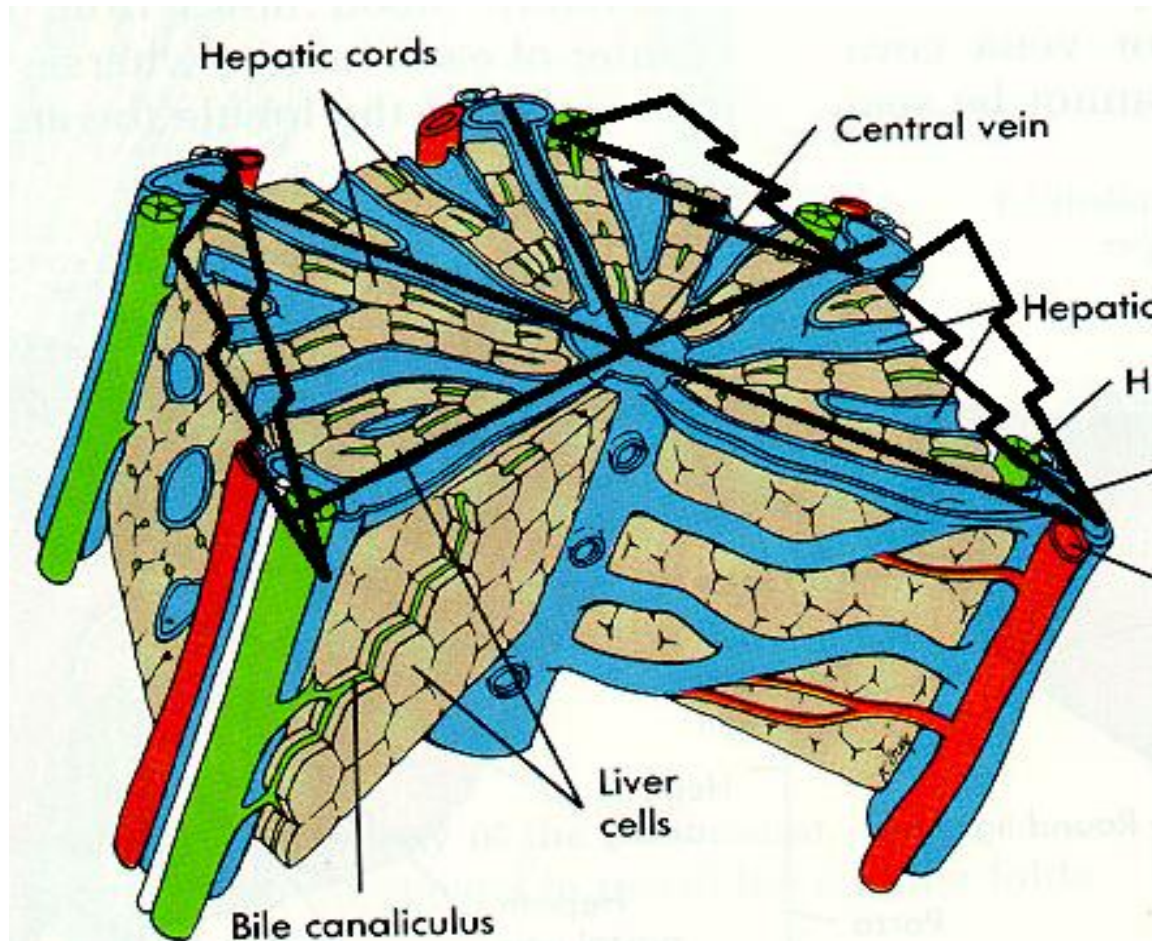
- Conceito;
  - Hepatopatia crônica, irreversível:
    - Fibrose
    - Desarranjo arquitetural
    - formação de nódulos de regeneração.









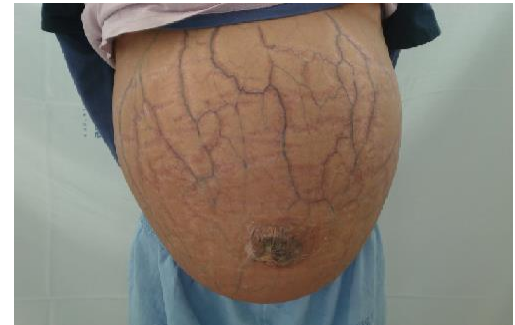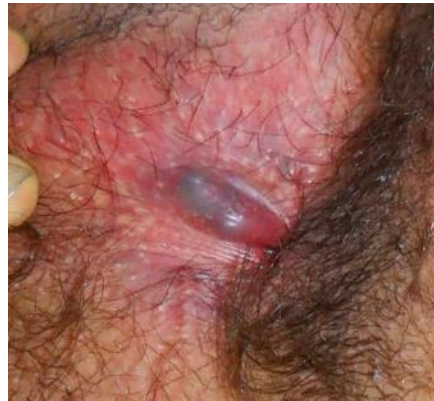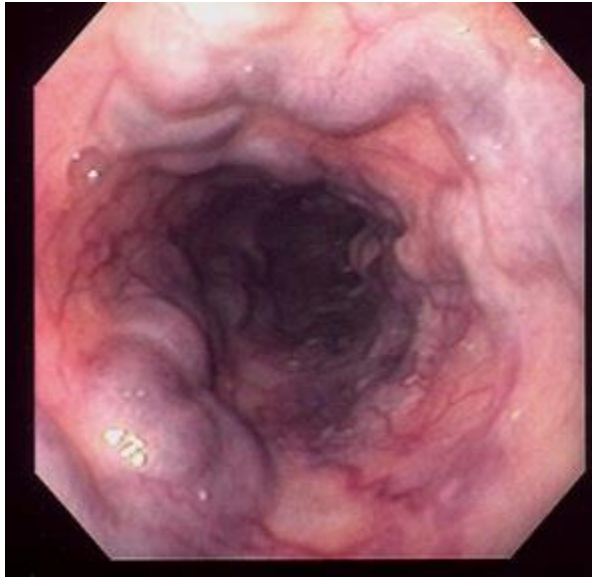


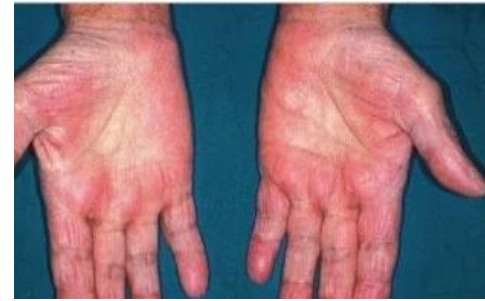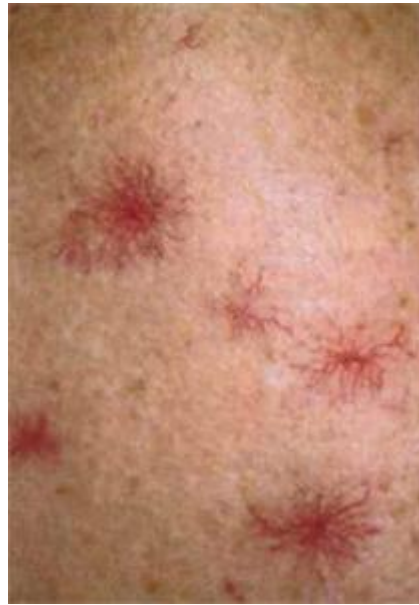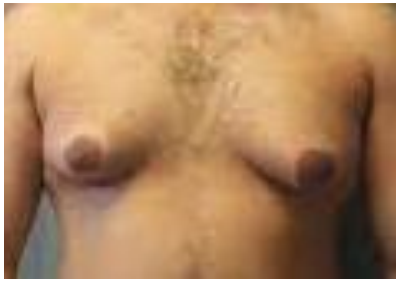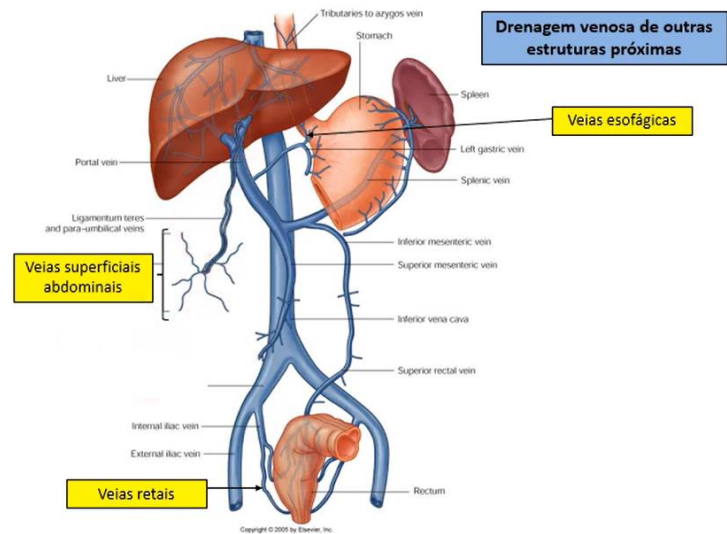
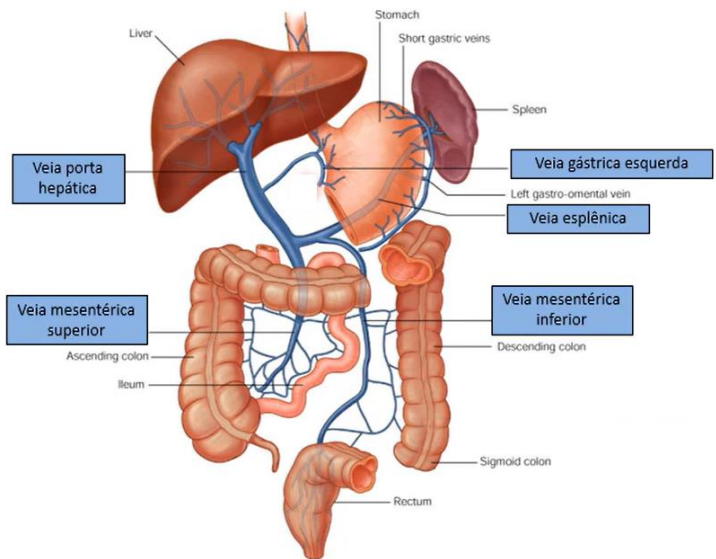
# Cirrose Hepática

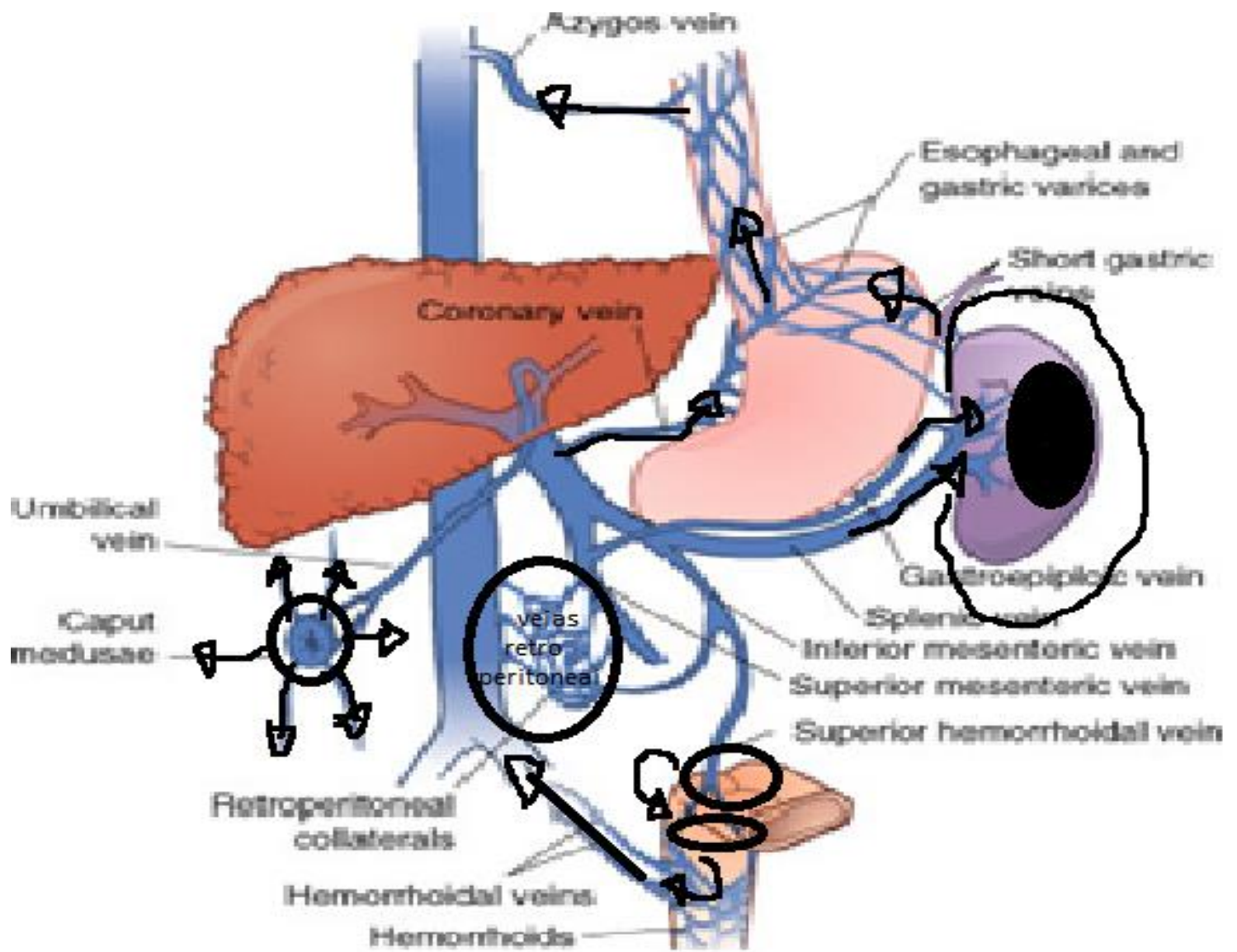
- Causas:
  - Alcoolismo
  - Hepatites virais (B/C)
  - Hepatite auto – imune
  - Doenças metabólicas
    - Hemocromatose
    - Doença de Wilson
    - Def. de alfa 1 – antitripsina
  - Cirrose criptogênica

# Cirrose Hepática

- Hipertensão porta
  - Varizes Esôfago
  - Hemorroidas
  - Circulação colateral
  - Esplenomegalia
  - Ascite
  - Colestase
- Insuficiência Hepática
  - Hiperestrogenismo
    - Ginecomastia
    - Aranhas Vasculares
    - Atrofia testicular
    - Rarefação de pelos
    - Eritema palmar
  - Coagulopatia
  - Hipoalbuminemia
  - Encefalopatia hepática
  - Sd. Hepatopulmonar
  - Sd. Hepatorenal









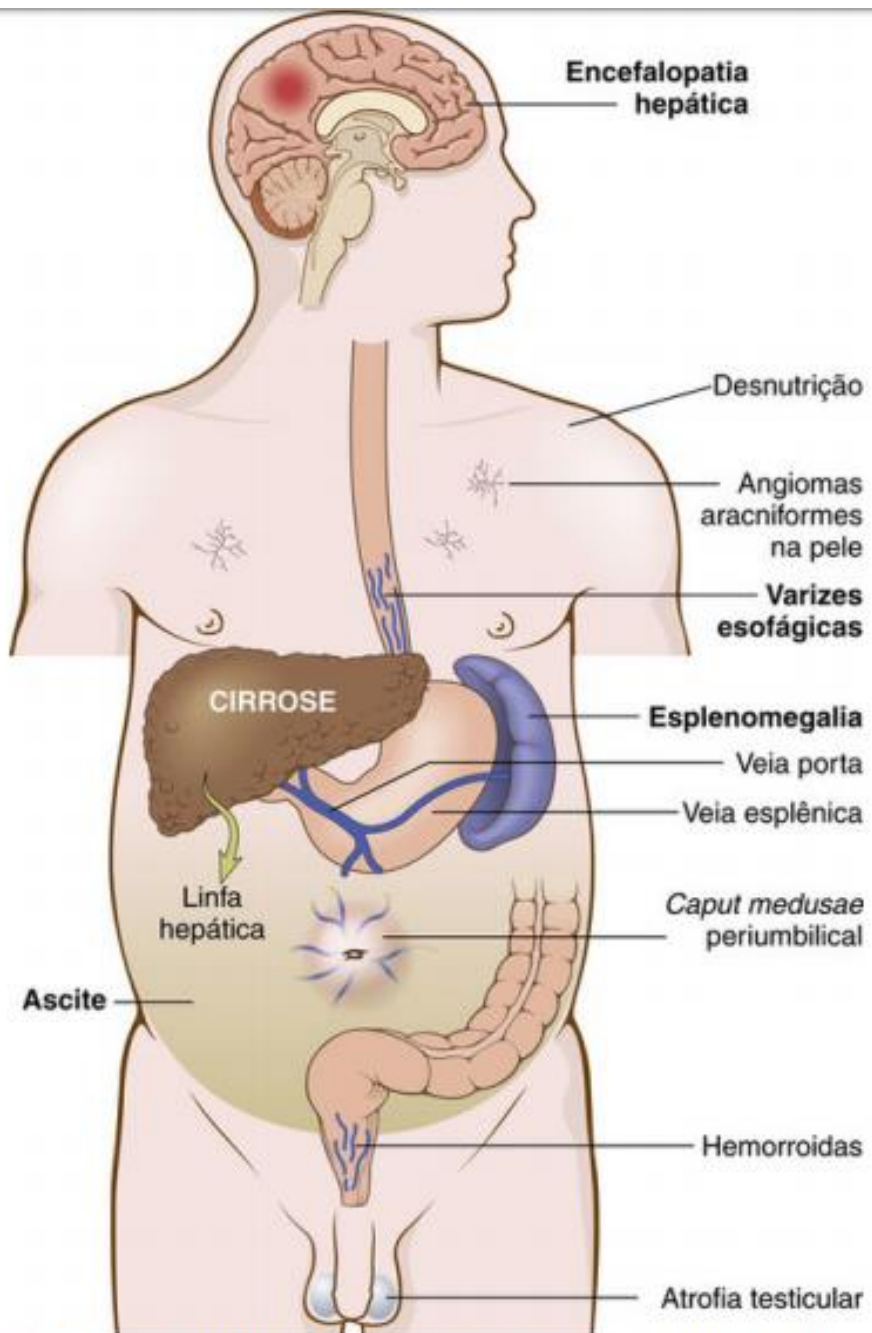
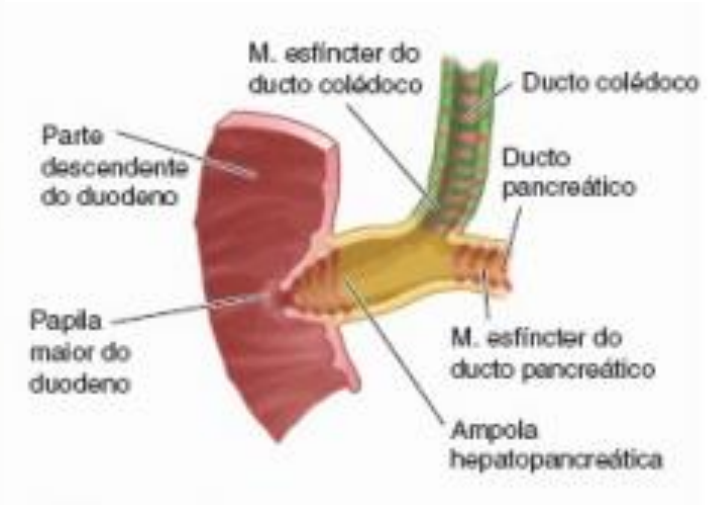
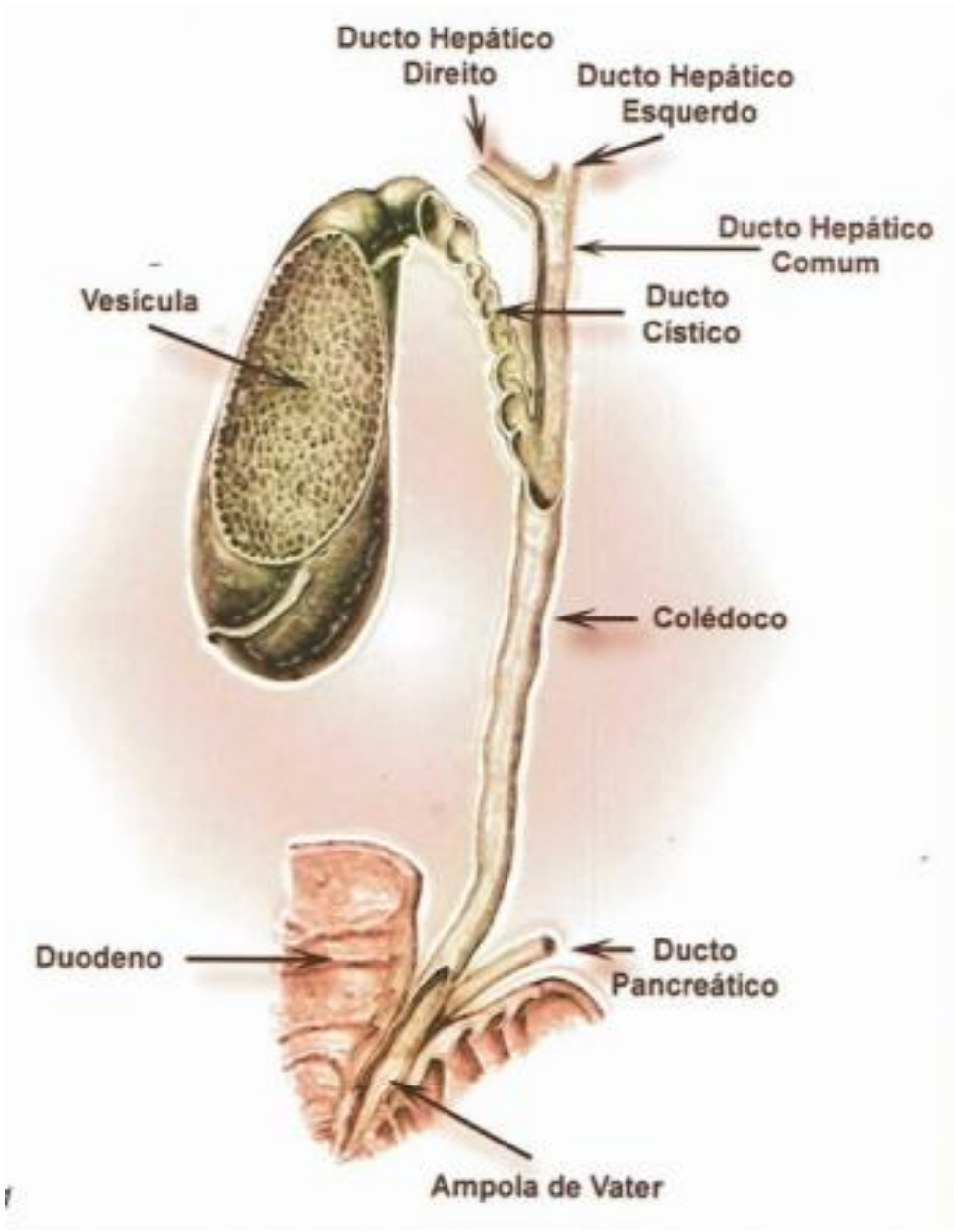
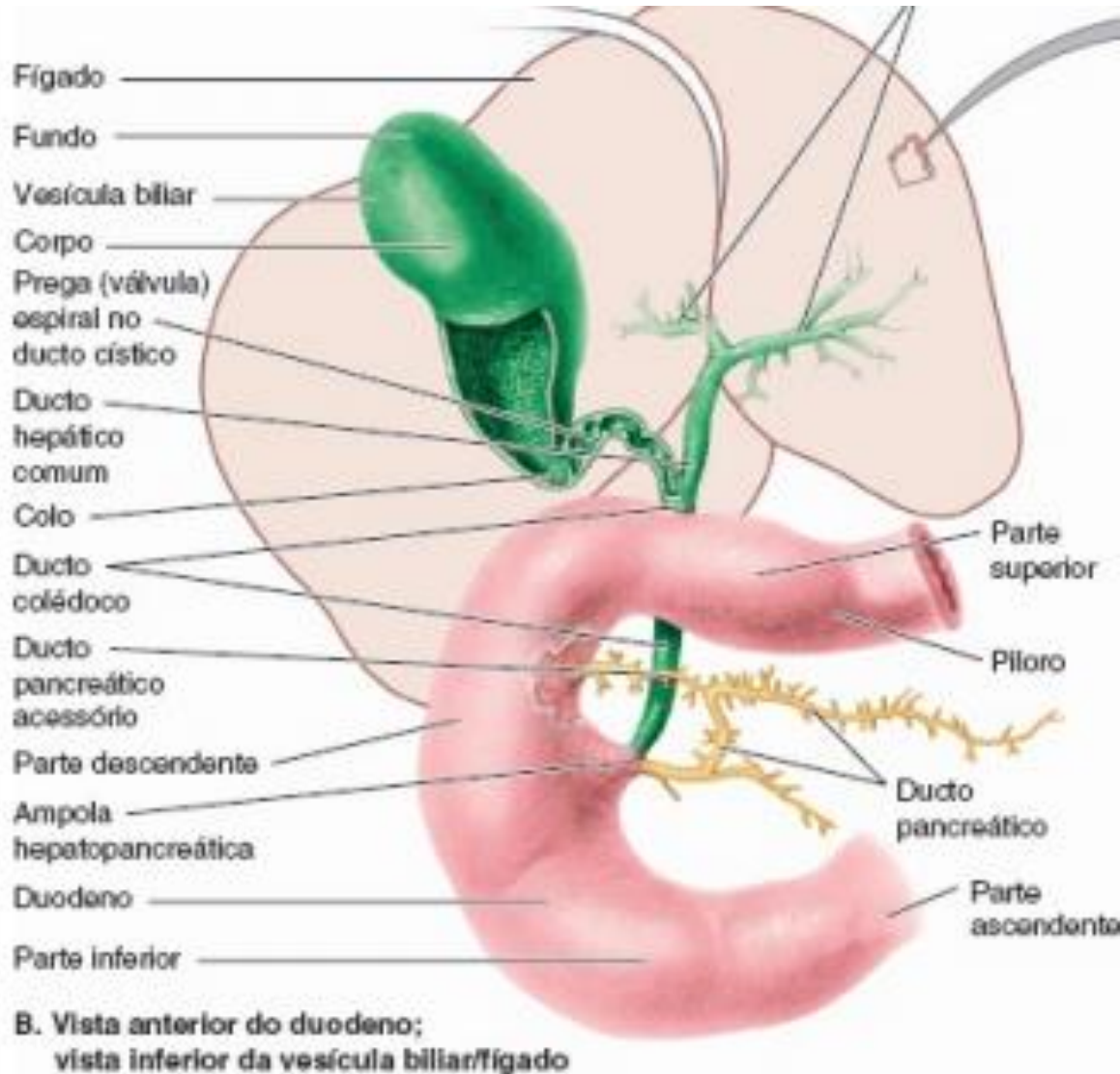


FIGURA 10.10 Manifestações clínicas da cirrose hepática. O fígado está marcado como "CIRROSE".

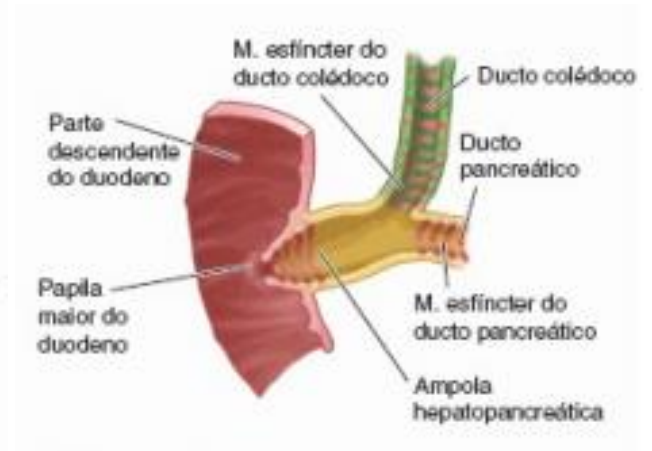
# **PATOLOGIAS DO TRATO BILIAR**



# Trato Biliar



Água, eletrólitos,  
colesterol, sais biliares,  
lecitina, bilirrubina

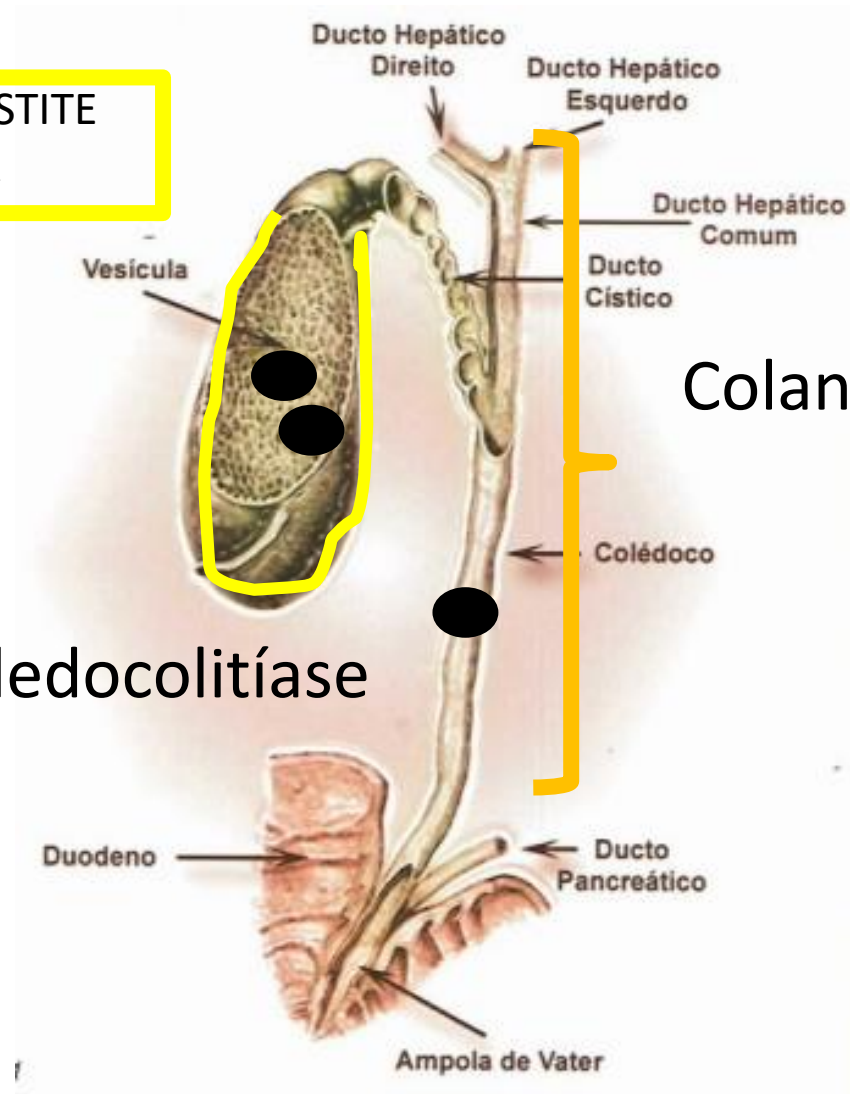


COLECISTITE  
AGUDA

Colelitíase ou  
colecistolitíase

Coledocolitíase

Colangite



# Trato Biliar

- Patogenia:
  - Saturação
  - Nucleação
  - Agregação

# Trato Biliar

- Tipos de cálculo
  - Colesterol
    - amarelo
  - Pigmentados
    - pretos
    - Marrons

# Trato Biliar

- Fatores de risco
  - Colesterol
    - Dismotilidade / estase
    - Multíparas, uso de ACO, mulheres
    - Obesidade e Emagrecimento rápido
    - Hipertrigliceridemia e uso de Fibrato
    - DC e Ressecção ileal



# Trato Biliar

- Fatores de Risco

- Bilirrubinato de Cálcio ( pretos)

- Anemia hemolítica crônica

- Pigmento marrom ou castanho

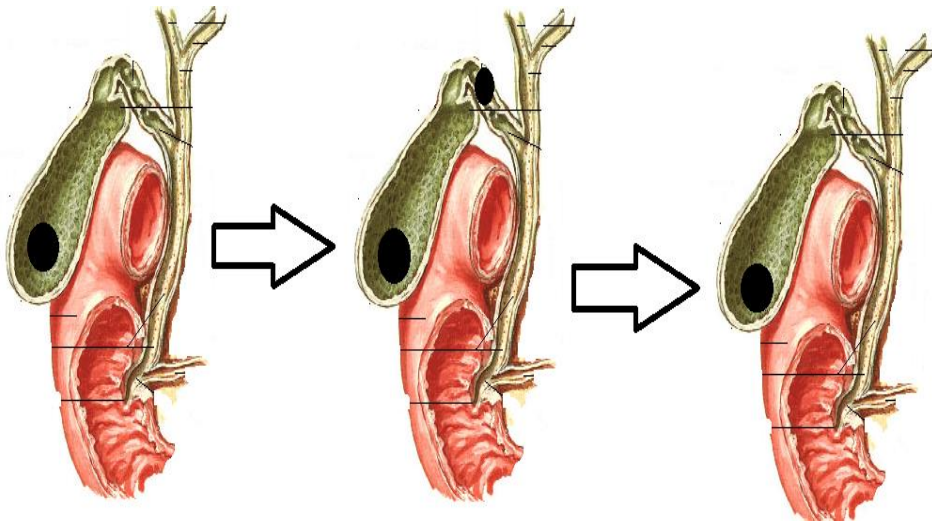
- Cálculo formado primariamente no colédoco.

- Estreitamento do colédoco

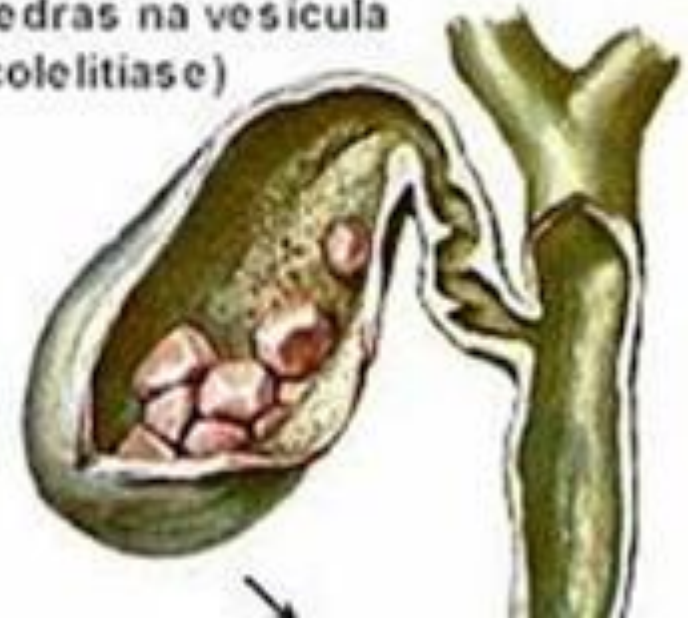- Parasitas na Via Biliar

# COLELITÍASE/ Colecistite crônica calculosa

- Conceito
  - SIMPLES presença de cálculo na vesícula biliar

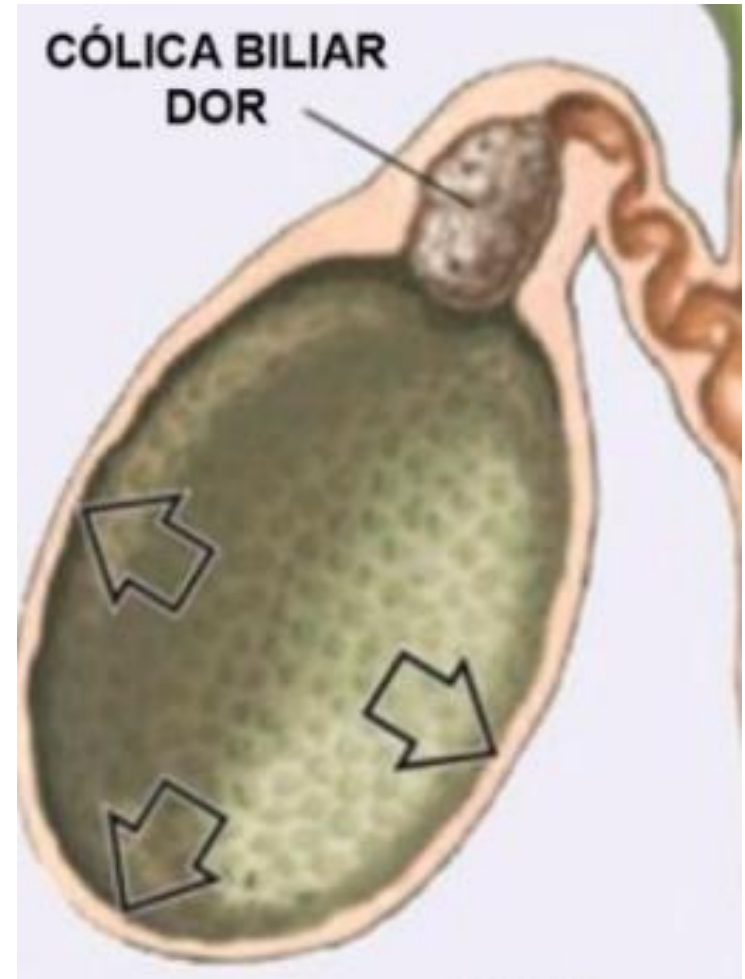
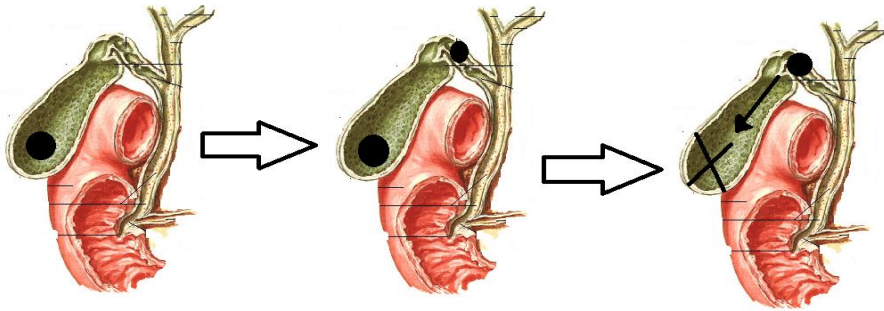


pedras na vesicula  
(colecistite)



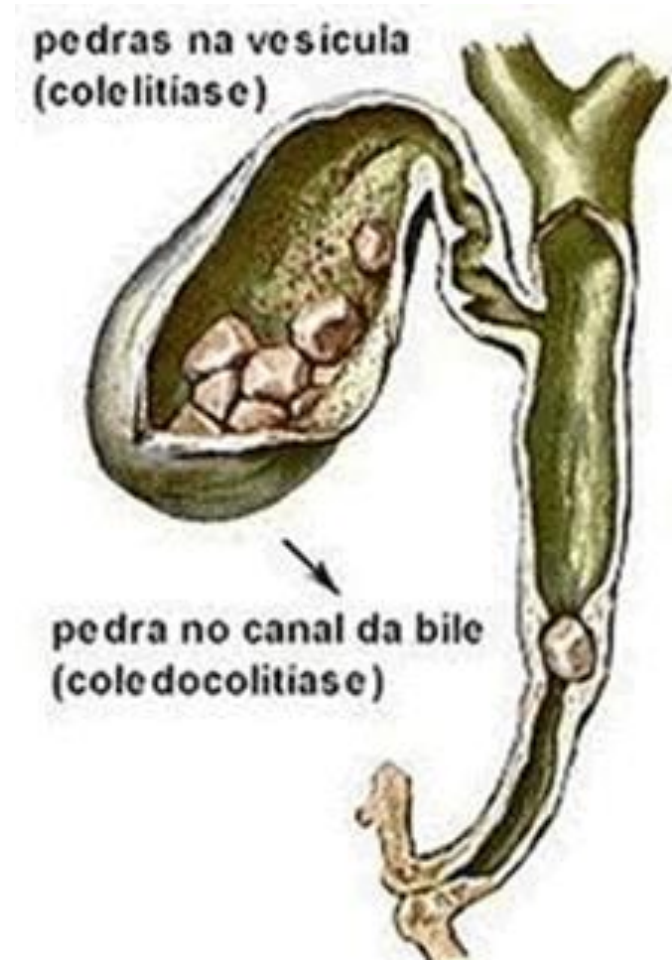# Colecistite Aguda

- Conceito
- Clínica
  - Cólica biliar
  - Febre + Leucocitose
  - Sinal de Murphy



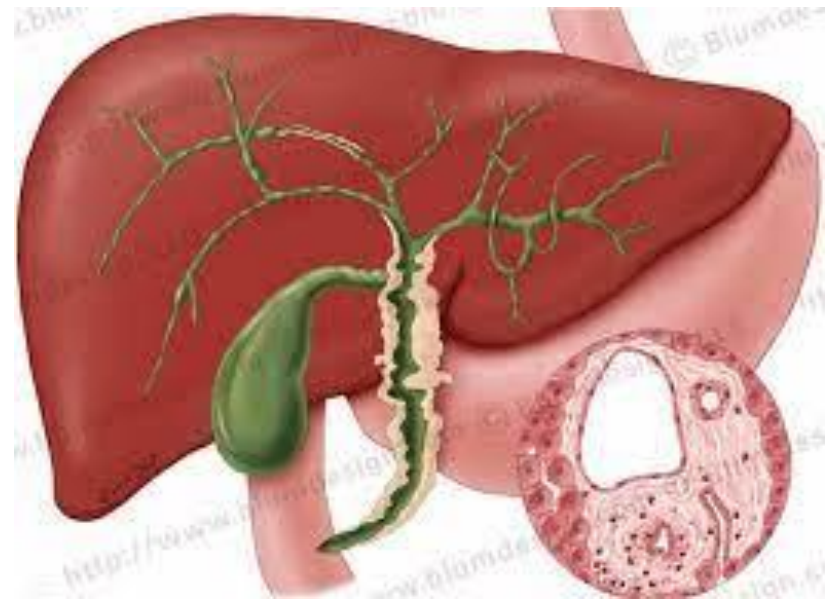
# Coledocolitíase

- Conceito
  - Presença de cálculo no colédoco
- Clínica
  - Icterícia + história de dor em cólica em Hipocôndrio direito
  - Icterícia flutuante



# Colangite

- Fatores Predisponentes
  - Coledocolitíase
  - Tumores Periampolares
  - Pós- manipulação das Vias biliares



# Referências

- Cecil
- Harrison
- Hobbins